

# EXTREMITAS

Journal of Lower Limb Medicine

Volume 2 • June 2015



Western  
University  
OF HEALTH SCIENCES

*The discipline of learning. The art of caring.*





---

# EXTREMITAS

*Journal of Lower Limb Medicine*

---

Thank you for taking time to peruse the second issue of Extremitas: Journal of Lower Limb Medicine. We at the Western University of Health Sciences take great pride in our interprofessional approach to patient care. Our authors astutely reflect this ideology through their writing in Extremitas, which includes a collection of work representing osteopathic medicine, podiatry, dentistry, and pharmacy. In the form of case studies, reviews, and editorials, our authors tackle controversial issues and refer to important literature. The result of their inquiry is ripe with important clinical, therapeutic, and surgical observations. They explore topics ranging from systemic rheumatic conditions to isolated neuroarthropathy, from surgical techniques and outcomes to management of complications, and litigious considerations to the history of mysterious disease. We hope this work peaks your interest in a subject and prompts you to delve further into it.

We would like to thank Western University of Health Sciences and the College of Podiatric Medicine, for this would not have reached your hands without their continued support. Please contribute your thoughts and feedback about any of this published work to the editors at [ExtremitasJournal@westernu.edu](mailto:ExtremitasJournal@westernu.edu). Once again, thank you for reading, and enjoy.

Sincerely,  
The Extremitas Editing Staff

# Extremitas Editing Staff 2014-2015



KELLY PARKS  
—  
Editor in Chief  
Class of 2016



KEVIN  
RAGOTHAMAN  
—  
Executive  
Assistant Editor  
Class of 2016



ADEL AITALI  
—  
Executive  
Assistant Editor  
Class of 2016



GINA  
NALBANDIAN  
—  
Assistant Editor  
Class of 2017



ANDREW YANG  
—  
Assistant Editor  
Class of 2017



KAREN MAST  
—  
Assistant Editor  
Class of 2016



DANIEL KIM  
—  
Assistant Editor  
Class of 2017

FACULTY MENTORS  
JARROD SHAPIRO, DPM  
DIANE KOSHIMUNE, DPM



# TABLE OF CONTENTS

---

<b>Epiphysiodesis Role in Lower Extremity Deformities</b> Caitlyn Lee MS2 and Rishika Lagiseti, MS2.....	7
<b>Functional Ankle Instability, Center of Pressure, and Stability</b> Jordan Crafton, MS2, Shayne Kelly, MS2, and Jordan Pitt, MS2.....	11
<b>Medical Malpractice vs. The Art of Medicine</b> Adriana G. Bumb, OMS2.....	13
<b>Maxillofacial Markers of Rheumatoid Arthritis: An Interprofessional Model for Detecting Lower Limb Pathology</b> Ho-Hyun (Brian) Sun, Second Year Dental Student, Sally S. Sun, Jason Y. Jung, and Supreeth Sharaschandra, MBBS.....	18
<b>A Biochemical Review of Charcot Neuroarthropathy and Treatment Options</b> Alex Dawoodian, MS4.....	24
<b>Evolution of treatment: The New Frontier of DVT Therapy</b> Mia Amanda Laurel, OMS4.....	28
<b>A Comparison in Gait and Other Parameters Following Treatment of Ankle Osteoarthritis with Tibio Talar Arthrodesis and Total Ankle Arthroplasty</b> Bryant Nachtigall, MS3.....	32
<b>Non-Conventional Treatments for Varicose Veins</b> Katherine Chao, Pharm.D.....	38
<b>The Phantom Limb – History and Reflection</b> Kevin Ragothaman, MS3.....	42
<b>Plantar Warts, Folklore, and the Placebo Effect- A Review</b> Colin McKay, MS2.....	46
<b>Case Study: Adult Acquired Talipes Equinovarus Deformity Secondary to Neuromuscular Disorder</b> Jared Leber, MS3.....	51
<b>Management of Lower Extremity Fracture Blisters</b> Dayna Chang, MS3.....	54



# Epiphysiodesis Role in Lower Extremity Deformities

Caitlyn Lee, MS2 · Western University of Health Sciences College of Podiatric Medicine

Rishika Lagiseti, MS2 · Western University of Health Sciences College of Podiatric Medicine

## **Introduction:**

Epiphysiodesis, since its discovery and initial use by Phemister in 1933, has become a primary treatment option for various deformities in both the podiatric and orthopedic communities. Written about and discussed by many, the procedure has been a treatment option for pathologies such as limb length discrepancy (LLD), juvenile hallux abducto valgus (HAV), and juvenile ankle valgus. A thorough analysis of the evolution and role of this surgical procedure in the scope of the foot and ankle was most recently conducted by Stuart J. Wertheimer, DPM in 1990. Since this time, there has been a greater interest in the technique. The purpose of this article is to review the role of epiphysiodesis in the treatment of lower extremity deformities as they have progressed since the previously mentioned evaluation and bring together the current knowledge and understanding of the procedure.

In essence, an epiphysiodesis can be described as a retardation and arrest of an entire growth plate or just along one side. Growth in the remainder of the plate is unaffected and as it progresses naturally can compensate for various pathologies, whether it be a coronal angle or length deformity. In this way, the procedure uses the natural bone growth potential as a means of correction.

## **Indications:**

The use of an epiphysiodesis as a method of treatment covers a broad range of pathology related to the lower extremity. Some of the major indications for the utilization of this procedure include limb length discrepancies (LLD), juvenile hallux abducto valgus (HAV), ankle valgus, and macrodactyly. Speaking more specifically of the podiatric indications, Wertheimer includes epiphysiodesis as a treatment option for juvenile Freiberg's infraction, brachymetatarsia, and local anterior cavus deformity. Indications determine both the necessity for surgical intervention and also which specific techniques can

be used. Our focus remains on the primary indications: limb length discrepancy, ankle valgus, juvenile hallux valgus, and macrodactyly.

### *Limb Length Discrepancy:*

The extent of the discrepancy is a major factor in evaluating whether surgical intervention is necessary for correction. A predicted limb length discrepancy of 2–5 cm at the time of maturity deems surgical intervention, specifically an epiphysiodesis, necessary for correction (4). A difference of less than 2 cm between limbs is, in most cases, asymptomatic and can be treated with conservative methods such as shoe lifts. Those above the upper limit of 5 cm call for a possible need for lengthening in addition to the epiphysiodesis.

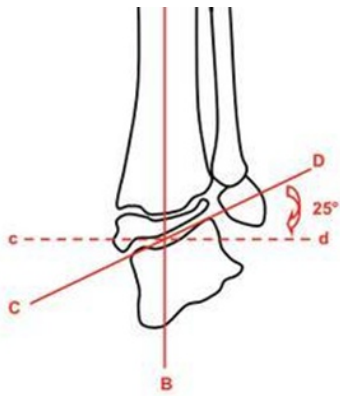
### *Hallux Abducto Valgus:*

The extent of deformity in this case is based on radiographic measurements of intermetatarsal angle (IMA), hallux abductus angle (HAA), hallux interphalangeus angle (HIA), proximal articular set angle (PASA), distal articular set angle (DASA), metatarsus adductus angle (MAA), and the metatarsal protrusion distance (MPD). A deviation of the respective angles from the normal values determines the extent of juvenile HAV. Further indication is based on skeletal age. The “golden period” of when this procedure should be conducted is between the age of 9 and 14 (1). Patients older than 9 years old have sufficient ossification to allow for staple purchase, whereas those younger than 14 years of age have yet to reach the adolescent growth spurt and have enough growth potential for correction.

### *Ankle Valgus:*

Ankle valgus is classified via AP weight bearing radiographs and the tibiotalar angle, an angle that is 90 degrees between the diaphyseal tibial axis and the tangential line to the talar dome (5). Pathological valgus was considered a tibiotalar angle of 10 degrees

or greater. Other researchers have used a variation of this method and measured ankle valgus with a variation of the same technique, utilizing a mortise view (10).



**Figure 1.** Talotibial Angle (5)

*Macroductyly:*

Macroductyly is a congenital condition that involves osseous and soft tissue enlargement and malformations which may impede the development of normal gait. Epiphysiodesis is used to arrest growth, especially in the hallux, instead of resection due to the importance the first ray has in normal gait and weight bearing. The aim for correcting macroductyly is not only cosmesis, but also to accommodate regular shoes. Correction of macroductyly with epiphysiodesis is usually done at a young age, but the exact timing depends on the severity of the malformation.

**Treatment:**

**Pre-operative:**

Preoperatively there is a consideration of clinical symptoms and disturbance to gait and overall quality of life. Each of the treatments is based on predicted correction at the age of maturity. This predicted value is determined by projections produced by various equations and charts based on the patient's skeletal age and maturity. Due to the fact that epiphysiodesis is a technique that uses the natural progression of bone growth, it is imperative that this procedure is done at the correct time to ensure full correction and avoid over correction.

This timing is determined by four basic methods: the multiplier, the growth remaining, the straight line graph, and the arithmetic method. Each method has its advantages and though none of them can be used

to predict exact values for corrections in LLD, the Green Anderson growth remaining method was found to be most accurate (11). It also must be noted that Bowen's chart of angular deformity vs. growth remaining is the only method that has been described to predict angular deformity.

*1. Multiplier Method*

The multiplier method uses equations to estimate the growth potential of bones in the leg and the foot in order to determine the length of the bones at skeletal maturity based on the multiplier table. This table is specific to gender, but is universal across ethnic and regional backgrounds. Using the calculated growth potential, which is a function of the amount of correction needed, and the estimated mature length, you can determine the age and bone length at which an epiphysiodesis should be performed on a patient. Because this method provides two determinants, the time of surgery is dependent on bone length if the actual age of the patient and length do not correspond to the calculated values.

*2. Growth Remaining Method*

This method is based on two charts of growth remaining based on bone age published by Green, Anderson, and Messner in 1963. Other growth remaining methods include Blais et al. growth prediction chart for the foot, Nelson charts that studied first metatarsal growth patterns, along with the Hoerr skeletal age atlas (1).

*3. Straightline Graph Method*

This method is based off the Green, Anderson, and Messner publication in which the charts are displayed as a graph and extrapolated to different ranges.

*4. Arithmetic Method*

The arithmetic method is primarily for LLD, shown to be applicable in children over 10 years and is based on two primary assumptions regarding skeletal growth. The first of these is that boys stop growing at the age of 16 while girls at 14. The second is that the distal femoral physes grow 10mm each year and the proximal tibial physes 6mm. Simple math is then used to determine predictive length at maturity.



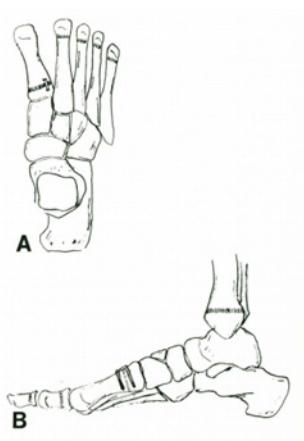
## Surgical options:

### *Screw:*

Screw epiphysiodesis involves utilizing the compression forces of the screw to prevent growth plate activity. Insertion of the screw can be done percutaneously and has shown to be reversible with removal if overcorrection seems imminent. This method is commonly used for ankle valgus, but can also be used for limb length discrepancy. For ankle valgus, the screw is inserted in the distal tip of the medial malleolus and traverses across and perpendicular to the growth plate. A retrospective review of the procedure states that this method can correct 10-15 degrees of ankle valgus and is a less morbid procedure compared to the alternative treatment using osteotomy and is minimally invasive with very little scarring (5).

### *Staple:*

The staple method is very effective in juvenile hallux valgus (JHV) to decrease intermetatarsal and hallux abductus angle. For JHV correction, the proximal arm of the staple is placed in the epiphysis parallel to the metatarsal cuneiform joint and the distal arm is in the metaphysis of the metatarsal. The staple is flush with the dorsal surface of the first metatarsal. This method is a better alternative to other soft tissue and osseous procedures that are associated with a high rate of deformity recurrence or postop disability while showing no sign of increased elevatus (1).



**Figure 2.** First metatarsal stapling for metatarsus primus adductus (12)

### *Bonebridge:*

The Phemister technique was discovered, as

described by Wertheimer, in 1933 primarily at the distal femur and proximal tibia as a treatment option for LLD. The procedure includes making a rectangular block cut of cortical bone including the physis. The physis is chiseled out and a bone bridge is created by reinserting the block 180 degrees to its original position. This method is now obsolete; instead, a percutaneous bone bridge is now used to achieve the same goal. It must be noted that this process is irreversible.

### *Canale Type Epiphysiodesis:*

The canale type epiphysiodesis includes ablating the physis by drilling and then burring. Authors found that this technique provided a mean correction of 2.5 cm with limited complications (8). This was the preferred procedure for the authors because it had fewer complications and is more successful in correcting the discrepancy over the screw method.

### Postop considerations:

Follow up appointments with radiographs are important to monitor progress and to detect overcorrection early. If epiphysiodesis is done too early, the deformity may be overcorrected, resulting in a deformity in the opposite direction. If using the screw or staple methods, overcorrection can be avoided by ablating or removing the screw or staple before the growth plate closes when the patient reaches skeletal maturity. This will restore normal growth across the entire physis and limit the degree of overcorrection. The bone-bridge and canale epiphysiodesis methods arrest the physis permanently and are irreversible. In this case, the only way to correct these procedures if there appears to be overcorrection or undercorrection is through an osteotomy.

### Outcomes:

Epiphysiodesis proves to have multiple advantages over other surgical techniques. The major advantage is that it allows for immediate postoperative weight bearing and a quicker recovery due to the fact that it is less invasive than an osteotomy. The percutaneous methods involve less surgical dissection, therefore, less morbidity and less postoperative complications. Performing this procedure at a young age is

advantageous because it allows for surgeons to use the patient's own natural bone growth to correct the deformity before it progresses and causes further pathologies. Research has shown that there is less risk involved and fewer long-term complications when choosing an epiphysiodesis over another surgical procedure.

### **Conclusion:**

As a surgical procedure, epiphysiodesis shows promise as a successful treatment option for a variety of pathologies and has a great potential for further research and development of different techniques and hardware.

### **References:**

1. C. Dickemore, R. Green, M. Zapf, D. Green. Epiphyseal stapling for juvenile hallux valgus. *Update* 203–214 (2006).
2. C. H. Chang, S. J. Kumar, E. C. Riddle, J. Glutting. Macroducty of the foot. *The Journal of Bone and Joint Surgery* 84, 1189–1194 (2002).
3. D. P. Paley et al. Multiplier method for predicting limb-length discrepancy. *The Journal of Bone and Joint Surgery* 82–A, 1432–1446 (2000).
4. I. Ghanem, J. A. Karam, R. F. Widmann. Surgical epiphysiodesis indication and techniques: update. *Wolters Kluwer Health* 53–59 (2011).
5. J.C. Auregan, G. Finidori, C. Cadilhac, S. Pannier, J.P. Padovani, C. Glorion. Children ankle valgus deformity transphyseal medial malleolar screw. *Orthopaedics and Traumatology: Surgery and Research* 97, 406–409 (2011).
6. J. Horn, R. B. Gunderson, A. Wensaas, H. Steen. Percutaneous epiphysiodesis in the proximal tibia by a single-portal approach: evaluation by radiostereometric analysis. *Journal of Child Orthopedics* 7, 295–300 (2013).
7. J. R. Davids, D. McBrayer, D. W. Blackhurst. Juvenile hallux valgus deformity: surgical management by lateral hermiepiphysodesis of the great toe metatarsal. *Pediatric Orthopaedics* 27, 826–830 (2007).
8. L.V. Babu et al. Epiphysiodesis for limb length discrepancy: a comparison of two methods. *Strat Traum Limb Recon.* 9, 1–3 (2014).
9. P. Stevens, R. M. Belle. Screw epiphysiodesis for ankle valgus. *Journal of Pediatric Orthopaedics* 17, 9–12 (1997).
10. R. K. Beal, M. Shea. Correlation of chronological age and bone age with the correction of ankle valgus by surface epiphysiodesis of the distal medial tibial physis. *Journal of Pediatric Orthopaedics B* 14, 436–438 (2005).
11. S. C. Lee et al. The accuracy of current methods in determining the timing of epiphysiodesis. *The Bone & Joint Journal* 95–B, 993–1000 (2013).
12. S.J. Wertheimer. Role of epiphysiodesis in the management of deformities of the foot and ankle. *The Journal of Foot Surgery* 29, 459–462 (1990).
13. T.A. Topoleski, A.Ganel, D.P. Grogan. Effect of proximal phalangeal epiphysiodesis in the treatment of macroducty. *Foot and Ankle International* 18, 500–503 (1997).

# Functional Ankle Instability, Center of Pressure, and Stability

Jordan Crafton, MS2 · Western University of Health Sciences College of Podiatric Medicine

Shayne Kelly, MS2 · Texas College of Osteopathic Medicine

Jordan Pitt, MS2 · University of Texas Medical Branch School of Medicine

## Introduction

Ankle sprains are the most common injury in athletes representing 15-20% of all sport injuries[3]. As with all injuries, ankle sprains cause residual effects including functional ankle instability (FAI). FAI is defined as recurrent sprains or a feeling of giving way in one or both ankles[5]. Much research has been done to understand the effects of FAI. The purpose of this abstract is to review five studies related to FAI, particularly its effects on the center of pressure (COP) during static single leg stance and gait and what can be done to decrease patient susceptibility to recurrent sprains.

## FAI on Static Single Leg Stance

Studies have looked at COP excursion due to peroneal muscle inhibition, mainly brevis and longus, through the use of stabilometry[1]. Stabilometry, which is defined as the calculation of a person's COP during particular postures, showed impairment on postural control during static single limb stance in the frontal plane when used on subjects with FAI [1,5].

Larger variations of COP occurred in subjects with FAI in comparison to those without. Movement of the COP was quantified by creating an ellipse around the points farthest from the initial COP in every direction. The area of the confidence ellipse for subjects with FAI was 394 mm<sup>2</sup> while those without FAI measured 254 mm<sup>2</sup>. In a study of 20 subjects with a history of unilateral ankle sprains compared to 30 subjects without this history, Cornwall and Murrell (1991) also found that the amplitude of movement in both the anterior-posterior and medial-lateral directions was significantly increased for those with FAI compared to the control group (Figure 1).

COP movement is highly correlated to the activity of the peroneal muscles. Peroneal muscles contract to create a medial displacement of the ankle joint and

COP shift. When postural control can no longer be maintained by the displacement of the ankle, the upper segments of the body adjust to help shift the COP within the area of support. This compensation occurs most often at the hip joint.

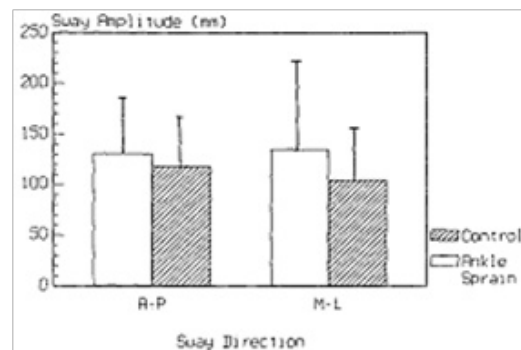


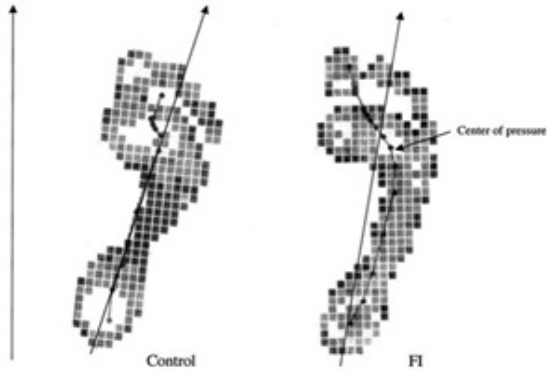
Figure 1. Effect of FAI on mean amplitude of postural sway (Cornwall and Murrell, 1991).

## FAI on Gait

Stability is also decreased during gait because of a lateral shift of the COP due to FAI. During gait, 12 young male FAI subjects compared to 12 healthy male subjects demonstrated a slowing down of weight transfer and increased forces on the lateral forefoot [3]. The time in which the COP was in different regions of the foot was measured and reported as a percent of total stance time. Individuals with FAI spent more time on their lateral forefoot than those in the control group (16.87 % compared to 15.47 %). The peak vertical ground reaction force in various regions of the foot was also measured. The FAI group demonstrated a significantly increased vertical ground reaction force on the lateral forefoot. This increased force occurred when the ankle was in an unstable, plantar flexed position which may increase susceptibility to sprains. No difference was observed between injured and uninjured legs in subjects with unilateral FAI, which suggests that their central control of gait may be altered[3].

Similar results were obtained by Nawata et al. (2005)

in a study of athletes with and without FAI by observing pronation-supination index. FAI subjects were found to have an increased pronation-supination index (53.9 to 46.5 degrees) at the mid-support phase of the gait cycle. A greater pronation-supination index suggests a lateral shift in COP as seen in Figure 2. No difference was seen at heel strike or toe off.



**Figure 2.** Lateral deviation of COP in FAI subjects compared to the control group.[2]

### Potential Causes and Solutions

Numerous articular nerve fibers terminate in mechanoreceptors in the capsules and ligaments of peripheral joints. Damage to these nerve fibers due to ankle sprains could inhibit proprioceptive ability and balance in those with FAI [1]. This could cause the slowing down of weight transfer from heel strike to toe off. In a study of female soccer players with and without FAI, ankle disk training was proposed as a mechanism to restore proprioceptive ability and improve postural control [4]. This training is accomplished via therapeutic exercises performed on a Bosu ball and is aimed to restore normal postural patterns. One example of an exercise is attempting to balance while standing on the Bosu ball with one foot. Additionally, Tropp and Odenrick (1988), in a study of 30 physically active men, 15 with FAI and 15 without, suggest that increased forces on the lateral forefoot may be due to weakened ankle pronator muscles that react more slowly in patients with FAI. Exercises focused on strengthening these muscles may enhance the ability of patients to make corrections in postural control at the ankle and thus protect against repeated sprains.

### Summary

Ankle sprains are the most common sports injury and cause many athletes to develop FAI. Research has been done which has increased our understanding of the effects of FAI on COP. Decreased postural control in static single limb stance, a slowing down of weight transfer, and a lateral shift of body weight during gait are significant alterations reflected by a lateral shift in COP in those with FAI. Of particular note, Bosu ball training to increase proprioception at the ankle joint is a possible treatment option for clinicians to use for FAI. Additionally, clinicians should consider exercises to strengthen ankle pronator musculature like the peroneus brevis and longus before exploring options for surgery. Further studies are necessary to determine what can be done to minimize these discussed effects of FAI on COP and stability. However, an understanding of lateral shift of the COP and stability changes can help clinicians understand the difference between a normal ankle sprain compared to someone with recurrent sprains and FAI. With this knowledge, they can educate their patients properly as to what their prognosis is.

### References

1. Cornwall, M. & Murrell, P. (1991). *J Am Pod Med Assn*, 81(5), 243-247.
2. Nawata, K. et al. (2005). *J Orth Sci*, 10(3), 298-301.
3. Nyska, M. et al. (2003). *Brit J Sport Med*, 37(6), 495-497.
4. Pintaar, A. et al. (1996). *Brit J Sport Med*, 30(2), 151-155.
5. Tropp, H., & Odenrick, P. (1988). *J Orth Res*, 6(6), 833-839.

# Medical Malpractice vs. The Art of Medicine

Adriana G. Bumb, OMS II · Western University College of Osteopathic Medicine of the Pacific

---

*Though it would seem that medicine and law are diametrically opposites, they come in uncomfortably close interplay when a case of legal medical malpractice is brought forth. In this article we will analyze a real case in which a patient considers pursuing a medical malpractice suit and discuss the relevant legal background.*

DP, a 10 year old male patient, sustained a displaced intra-articular right calcaneal fracture after falling from an approximate 6 foot height and landing on his feet. A team consisting of an orthopaedic surgeon and podiatric co-surgeon performed surgery to restore alignment and contour by open reduction and internal fixation with calcaneal plating.

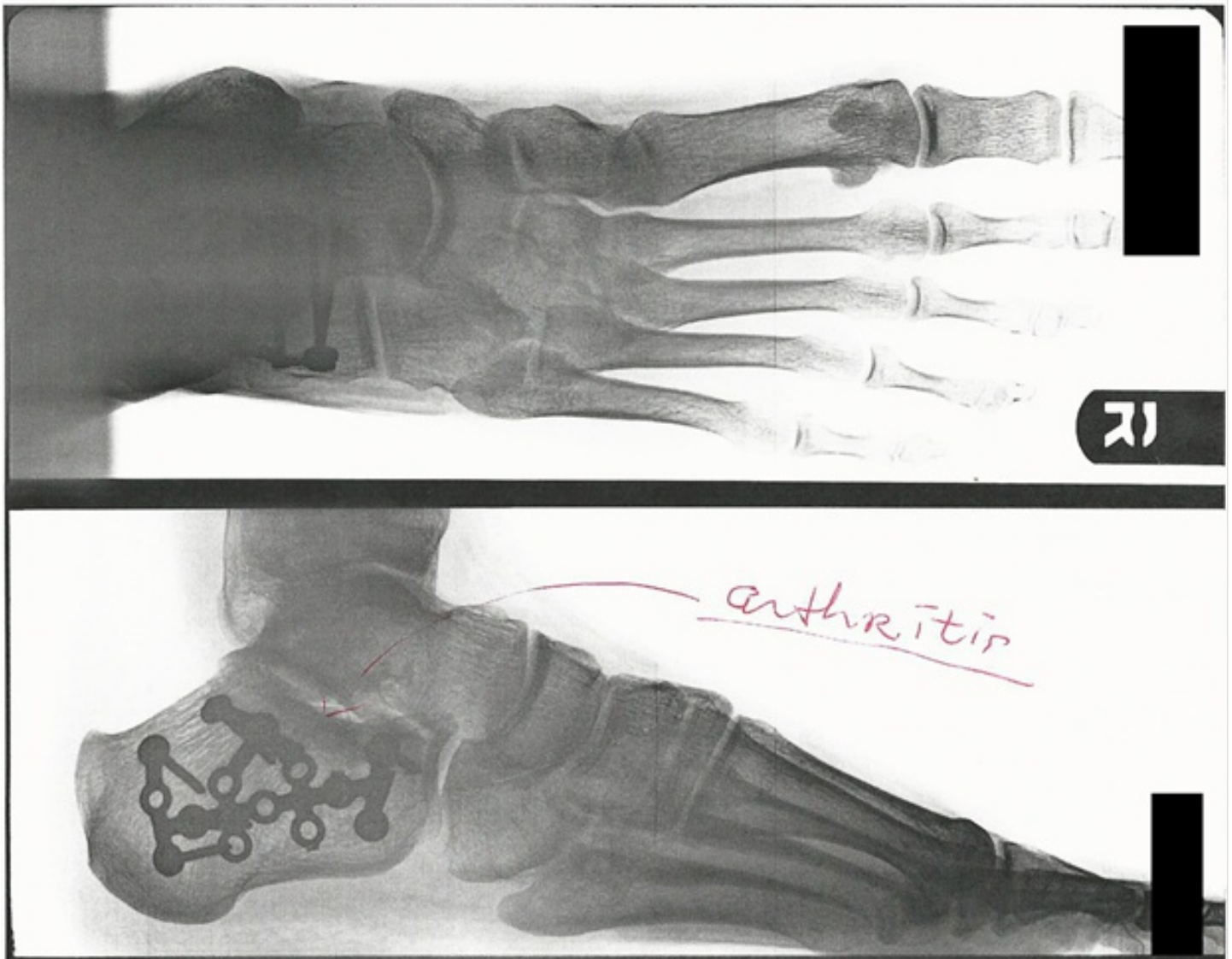
Surgical notes are verbatim as follows:

The procedure, alternatives, risks, and benefits were discussed with the patient's family, all questions were answered, and they expressed understanding of the aforementioned discussion. The patient was then taken to the operating room. A lateral flap was made, and this was carried down sharply through skin and underlying subcutaneous tissue with care to protect the peroneal tendon. This flap was raised off the bone. This revealed the subtalar joint. Pins were then placed in order to retract the flap. The fracture had a significant amount of healing, so the callus was removed, and then the fracture fragments were then loosened up. A large diamond pin was then placed in the heel from lateral to medial. This was used to reduce the tuberosity and pull it out as well as translate it medially. Then, the intraarticular pieces were reduced and held with pins. The calcaneal plate was then contoured and then attached in standard fashion. Intraarticular x-ray showed a good reduction as well as placement of the implants. Wound was irrigated, closed in a serial manner, and then a dry sterile dressing was applied, and then a well-padded splint was applied.

Approximately 7 years status post right calcaneal fracture surgery as described above, DP presented to a different podiatry office with a concern of severe pain in his right foot at and around the surgery site. He was unable to participate in school PE and weight training class due to the debilitating pain. On physical exam, Dr. M, the new podiatrist, noted signs of post-traumatic arthritis manifested by mild swelling around the subtalar joint and associated popping and clicking upon weight bearing. X-rays and CT scan were consistent with the physical findings and also demonstrate subtalar joint arthritis (Figure A-1). Additionally, X-rays and CT scan demonstrated retained screws and plate. Dr. M described his impression of the patient's surgical outcome, 7 years post open reduction and internal fixation, as that of "a 70-year-old ...status post right calcaneal fracture". Based on these finding, Dr. M advised that it would be recommended to have the orthopaedic implants removed as he determined that the source of DP's pain was partially due to irritation from the hardware.

The patient agreed to the procedure and Dr. M performed the surgery to remove the orthopaedic implants. Dissection was carried out to full thickness; however, approximately 50% of the calcaneal plate had been overgrown with exuberant bone (Figure A-2). At the point this became apparent during the procedure, the surgeon, Dr. M, decided that the removal of the posterior superior portion of the plate would be overall too destructive. Other screws in the mid and distal portion all along the peroneal tendon were removed as there was evidence of inflammation along the peroneal tendon. Additionally, the peroneal tubercle was burred smooth

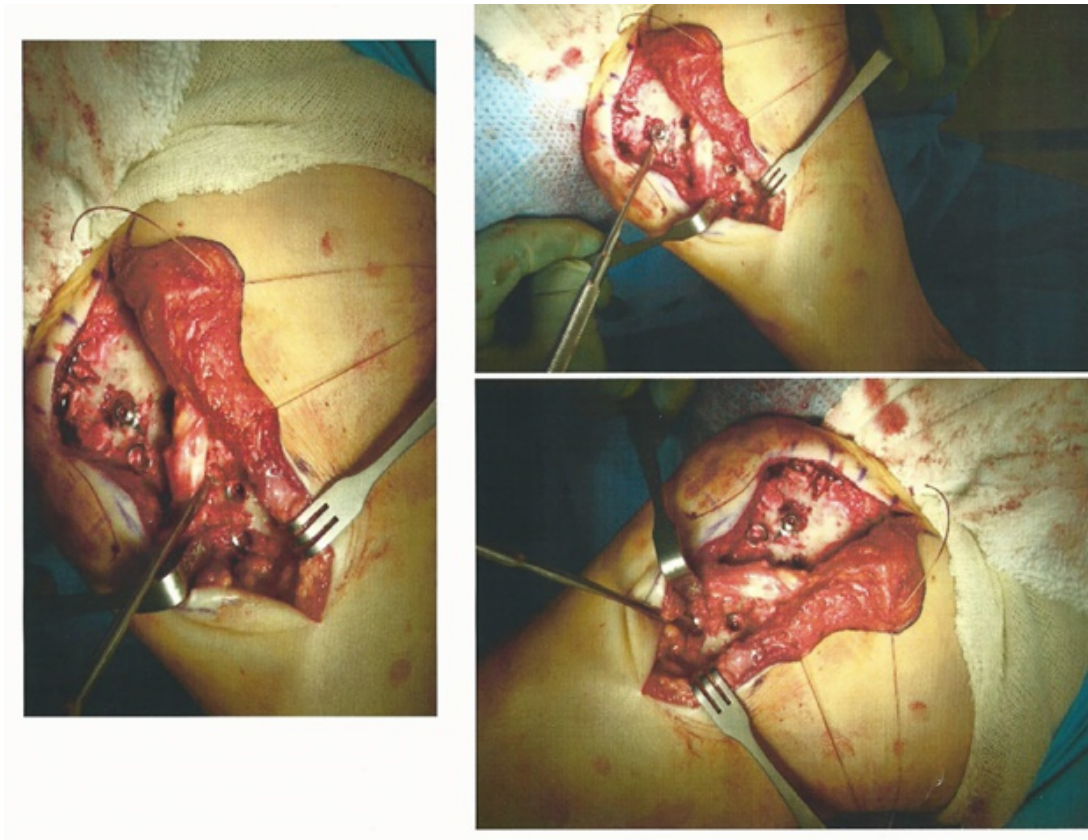
and this appeared to provide significant decompression. The procedure end point provided exostectomy of lateral peroneal tubercle and right calcaneal screw removal with the plate remaining intact. Photo documentation associated with second surgery, performed by Dr. M is included to follow (Figure A-1 and A-2).



**A-1:** Pre-op x-ray imaging performed prior to second planned surgery for removing the orthopaedic implants. Bottom picture shows locking calcaneal stainless steel plate. Note locking screws are optional for each available whole. Arthritis at the subtalar is noted by the physician with the red arrow.

Post-operatively, the rigid internal fixation hardware in place allowed for early mobilization, therefore motion was advised following postoperative dressing removal, two weeks post-operatively. DP was able to resume normal activity approximately 3-4 weeks post-operatively and reported improved exercise tolerance with considerable pain relief in comparison to his pre-operative status. However, DP continued to experience pain related to the arthritis as well as other injury and surgical consequences.

From the patient's perspective, it would go to follow that since the pain had decreased with partial removal of the implants there might have been better results if all the implants could have been removed as planned, or more preferably still, removed at the optimal time before the orthopaedic implants could have become overgrown with bone.



**A-2:** Intraoperative photos capture showing significant bone overgrowth covering the calcaneal plate.

The patient and his representatives are considering filing a malpractice suit alleging that the original surgeons failed to advise regarding the removal of the orthopaedic implants and an appropriate timeline for removal. Such disclosure was allegedly not verbalized to the patient or his representatives nor was any such disclosure found in the surgeon's report or documents pertaining to the surgery. The patient believes that had he known to pursue surgical removal of the orthopaedic implants sooner, he would have done so, and would perhaps have reduced and/or prevented the severity of arthritis and other long term damage related to irritation from the orthopaedic implants.

Does this case have grounds to prevail in court?

### **Medical Malpractice Background and Case Review**

Under certain exceptional circumstances, gross medical malpractice acts of a criminally inclined practitioner could prove 'substantial and unjustifiable risk' and could therefore be pursued in criminal court, such as the infamous case against Dr. Conrad Murray, the house-call physician of Michael Jackson. However, this is not the case in the situation we are analyzing. Ordinarily, medical malpractice cases are regarded as tort action pursuant to alleged negligence and are pursued in civil court. Proof for this type of case requires a 'preponderance of evidence', as opposed to 'proof beyond reasonable doubt' for criminal cases.[3] The burden of proof is incumbent upon the instigator, and as such the plaintiff must prove the four elements of negligence, which are as follows:

- 1) An established patient-doctor relationship;
- 2) An established duty on the part of the physician;
- 3) A breach of this duty on the part of the physician; and
- 4) A causal relationship between the breach of duty and an injury to the patient. [5]

As with an ever growing number of cases, miscommunication, or lack thereof, seems to be at play in this case in which the patient, DP, claims a failure on the part of the first team of surgeons to provide information regarding his condition and follow-up with regard to the orthopaedic implants and the need for future removal. [4] This could have easily been avoided if the aforementioned concerns had been discussed and documented as part of the informed consent and Procedure, Alternatives, Risk and Questions (PARQ) Conference. As a general standard, the informed consent process should include the following:

- 1) A description of the proposed procedure in terms commensurate with patient's capacity;
- 2) Any alternative procedures or approaches to the proposed treatment; and
- 3) Disclosure of risks associated with the proposed procedure. [5]

Despite the fact that there is no evidence to support a discussion surrounding this particular aspect of the procedure, referring to the removal of the orthopaedic hardware, it would be difficult to prove the second element of negligence - duty. Removal of orthopaedic plates is rather controversial within the field of orthopaedics and podiatry. In this case it seems that the surgeons who placed the plates and screws would be proponents of a non-removal practice, whereas the podiatrist who attempted to remove the plates would have proposed the removal of the plates within approximately 2-3 years of their placement. This kind of variation in practice is what the art of medicine practically entails, though it does bring controversy. In consideration of this controversial issue and due to the fact that medical cases almost always involve implications outside of the jury's common knowledge, the plaintiff would need to retain expert medical witnesses to help prove their case. Ultimately, this case would likely be a discretionary decision based on further third party testimony which may or may not serve to prove duty.

Moreover, perhaps the most difficult part of this legal case would be to prove the fourth element of negligence-causation. To satisfy 'cause-in-fact' causation criteria, the traditional causation requirement is proof of the 'but-for' rule whereby the plaintiff must demonstrate that the injury would not have otherwise occurred in the absence of the defendant's actions, or lack thereof, – in other words, that the defendant's actions independently caused the defendant's alleged injuries. In this case however, two separate events could each, plausibly and independently, have caused the patient's pain, inflammation and arthritis: (1) the original traumatic injury alone, and/or (2) the placement/presence of the orthopaedic implants. Concurrent causes and combined causes complicate the 'but-for' test for causation and therefore these facts alone would be insufficient to satisfy the jury. [1]

Alternatively, the courts would then require proving 'proximate causation', whereby the plaintiff would have to prove that the defendant's actions, or lack thereof, were a 'substantial factors' in the alleged injuries. In this particular case, even in the event that the orthopaedic implants had been removed completely at the optimal time, it is uncertain if the patient would have been better relieved of his pain or that his arthritis would not have developed following the original traumatic injury- that is, either with or without intervention. In fact, some residual pain after an injury of this magnitude is common and post traumatic arthritis is a well-documented phenomenon, ergo 'substantial cause' would likely be unsatisfied. [1]

Therefore, on preliminary review, it would appear that this case brought forth in court would be unlikely to succeed. As a general consideration, a 2006 study found plaintiffs winning only 21% of their cases and of these, 80% involved serious injury or death.[2] This would seem to indicate that substantial and unequivocal losses would need to be proven in order to prevail in court. Practicing competently, communicating clearly with accurate information and allowing patients the freedom to weigh-up their options are all important factors which can help avert malpractice litigation to begin with.



*Take-away: The four elements of a negligence tort must each be proven in order to win a medical malpractice suit. Providers should be aware that it is their duty to practice the art of medicine in the manner they best see fit but alternatives to the standards of practice must be clearly communicated to patients, allowing the patient to have their rightful part in medical decision making.*

**Disclaimer: The information contained herein is strictly informational; it is not to be construed as legal or medical advice.**

### **Resources**

1. Benjamin C. Zipursky, Foreseeability in Breach, Duty and Proximate Cause, 44 Wake F. L. Rev. 1247, 1253 (2009). The full text of this article is available online at <http://lawreview.law.wfu.edu/documents/issue.44.1247.pdf>. Accord *Lubitz v. Wells*, 113 A. 2d 147 (Conn. 1955).
2. "Facts and Myths About Medical Malpractice." MedMalfacts.com. N.p., n.d. Web. 5 Dec. 2014. <<http://www.medmalfacts.com/about-medical-malpractice/>>.
3. James A. Filkins, With No Evil Intent: The Criminal Prosecution of Physicians for Medical Negligence, 22 J. Legal Med. 467, 472 (2001)
4. Nance, Reba J List. "The Top Ten Causes of Malpractice - and How You Can Avoid Them." Colorado Bar Association (n.d.): n. pag. Web. 5 Dec. 2014.
5. Wachter R.M. (2012). Chapter 18. The Malpractice System. In Wachter R.M. (Eds), *Understanding Patient Safety*, 2e. Retrieved January 03, 2015 from <http://accessmedicine.mhmedical.com.proxy.westernu.edu/content.aspx?bookid=396&Sectionid=40414552>.

# Maxillofacial Markers of Rheumatoid Arthritis: An Interprofessional Model for Detecting Lower Limb Pathology

**Ho-Hyun (Brian) Sun, MS\*** · *Second Year Dental Student, Western University of Health Sciences*

**Sally S. Sun\*** · *Community Health Coordinator*

**Jason Y. Jung** · *Undergraduate Student, Boston College*

**Supreeth Sharaschandra, MBBS** · *Physician, Private Practice*

*\*These authors have contributed equally to this article.*

Rheumatoid arthritis (RA) is a systemic autoimmune disorder that affects over 1.3 million adults each year in the United States<sup>1</sup>. Though the exact etiology is unknown<sup>2</sup>, it is characterized by inflammatory destruction of synovial joints. RA is often associated with self-recognition of major histocompatibility complex II (MHC II) molecules<sup>3</sup>, particularly the HLA-DR subtype<sup>4</sup>. Overall, RA is a highly debilitating disorder characterized by immobility, joint pain, and disfigurement of the bony junctions. It commonly manifests in the joints of the ankles and feet as well as the knees and fingers, though it can also present as an autoimmune attack on the internal organs of the patient<sup>5</sup>.

As a result of its common manifestation in the foot and the ankle, RA is a significant contributor of lower limb pathology and a major concern in podiatry. RA affects approximately 1% of the population worldwide, with over 90% of these patients reporting debilitating issues below the knees<sup>6,7</sup>. These numbers suggest that podiatrists may be best equipped to understand the implications and treatments of rheumatoid arthritis in a patient's livelihood. Unlike other healthcare practitioners, podiatrists are able to address the autoimmune components of disease through pharmacological prescriptions while concurrently limiting further mechanical damage through individualized orthotics and appliances. Considering the unusual pathologic profiles of the weight bearing structures and the unique skill set of a lower limb specialist, potential cases of RA may be best directed to the care of a podiatric physician.

Unfortunately, because of the constant pressure exerted on the lower limb joints, their involvement leads to unusually large degree of dysfunction. Investigators have found that the majority of RA patients quickly become victims of lower limb pathology as they lose workplace mobility within

about 10 years of disease<sup>7</sup>. Aside from difficulties in the workplace, over 68% of RA patients report moderate to severe foot pain daily<sup>8</sup>, impinging upon their ability to maintain normal lifestyles. Overall, RA patients exhibit slower walking speeds, longer double-support phases, as well as reduced heel rise angles indicative of difficulties with locomotion and a significant decrease in quality of life<sup>9</sup>. So far, podiatric appliances or foot and ankle surgery have been shown to be one of the few effective methods of mitigating impaired lower limb mobility from RA.

Previous studies have shown that rheumatoid treatment leads to the greatest alleviation of symptoms such as pain when the treatments applied early and aggressively<sup>10</sup>. Two diagnostic modalities, radiographic imaging and blood tests, have been established for rheumatoid arthritis, though the x-ray images can only detect the disease after the joints have already eroded significantly<sup>11</sup> while serum tests are often not very specific<sup>12</sup>. However, new studies are beginning to suggest that lower limb RA is also detectable by readily visible, noninvasive methods involving the patient's own face. Evidence indicates that rheumatoid patients often first experience maxillofacial pathology, and that several maxillofacial conditions may serve as reliable indicators for undetected rheumatism elsewhere in the body<sup>13-17</sup>. Accordingly, the aim of this review is to explore the viability of accessible markers of RA and to detail the evidence in support of their accuracy for the purposes of detecting rheumatic disease. Furthermore, we propose a new paradigm of healthcare of RA care in podiatric centers, especially in light of the profound sensitivity of the lower limbs towards RA. In doing so, it is the authors' hope that a manageable clinical and public health model can be established to limit the overall burden of RA on future patients.

## Ocular Markers of Rheumatoid Arthritis

Keratoconjunctivitis sicca (KCS) is perhaps the best known example of RA-linked pathology within the maxillofacial region. Though KCS is not a disease of a physical joint, it is an autoimmune disease characterized by redness, dryness, and burning sensations of the eyes caused by inadequate tear production. Notably, cases dating half century or more have linked the presentation of KCS with rheumatoid arthritis. An investigation from 1956 by Thompson and Eadie has found that 14 out of 18 cases of KCS were also positive for signs of rheumatoid arthritis<sup>16</sup>, while a more recent study by Mody et al confirmed that RA and KCS occur concurrently in 50% or more of the cases<sup>15</sup>. Like RA, the autoimmune association of KCS is well established; researchers now believe that the patient's own immune system is responsible for degrading the lacrimal glands that helps maintain ocular moisture<sup>18</sup>. Interestingly, HLA-DR genetics are implicated in the proposed pathophysiology of both KCS and RA, leading to further suspicions that the two diseases are fundamentally linked<sup>18,19</sup>. Though this hypothesis requires further exploration, the delicate nature of lacrimal tissues may explain their peculiar susceptibility to autoimmune damage, even more so than are the connective tissues of the joints.

## Mucosal Markers of Rheumatoid Arthritis

Another well-known pathology linked to RA is xerostomia, or the disease of dry mouth. Xerostomia is characterized by constant discomfort and difficulty swallowing associated with hyposalivation<sup>20</sup>. It is believed to be an autoimmune disease that utilizes the patients' own immune cells for salivary gland destruction<sup>21</sup>. In a study of 604 rheumatoid arthritis patients, dental investigators found that over 60% of the individuals reported at least mild signs of xerostomia while approximately 43% of the subjects were found to have several severe symptoms<sup>22</sup>. Thompson and Eadie's study from the 1950s has also shown a 78% likelihood of co-presentation of RA with xerostomia<sup>16</sup>. Like lacrimal tissues, salivary glands are delicate secretory organs responsible for the protection of exposed epithelium. Their susceptibility to autoimmune damage is demonstrated in Sjogren's Syndrome, where both the lacrimal and

salivary glands are destroyed by autoimmune antibodies - particularly in response to a faulty HLA heterodimer<sup>23</sup>.

## Skeletal Markers of Rheumatoid Arthritis

RA has become a growing concern partly because of the rising numbers of periodontitis patients among RA sufferers. Periodontitis is defined as the inflammation and destruction of the alveolar bone surrounding the jaws and the maxillary sinuses. Perhaps not surprisingly, periodontitis is also considered to have a large autoimmune component as much of the destruction is linked to indiscriminate immune attack originating from the oral cavity<sup>24</sup>. Unlike the internal joint capsules, the warm, moist, yet easily accessible conditions of the mouth makes it a constant battle ground between arriving bacteria and the body's own immune response. As oral lymphocytes are continuously activated, they become much more likely to launch an unwanted attack against the nearby maxillofacial region<sup>25</sup>.

Studies have found that there was a significantly higher incidence of alveolar bone degradation and associated tooth loss in rheumatoid arthritis patients<sup>13</sup>. In another review, the investigators have found that RA patients are more than eight times as likely to also be classified as periodontitis patients by their dental professionals<sup>26</sup>. In addition, studies in animal models show that rats with RA have significantly increased levels of periodontitis biomarkers compared to healthy subjects<sup>27</sup>. Periodontitis may serve as yet another revealing sign of an autoimmune condition deep within the synovial joints, especially because evidence suggests that periodontitis is not restricted to individuals with particularly higher levels of oral flora<sup>24,25</sup>, but that it is positively implicated to changes in the HLA-DR subtypes<sup>13,28</sup>. Hypothetically, the heightened sensitivity of the perioral lymphocytes could lead to a more rapid autoimmune destruction of jaw bones before RA can manifest in the extremities.

## The Common Mechanism

Edwards and colleagues suggested that the advent of many autoimmune diseases is linked to the activity of T-cell subverting B cells<sup>2</sup>. It is possible that a misappropriated memory response via these B cells is

responsible for eliciting an attack against self-antigens. In fact, recent clinical findings have shown that autoimmune rheumatoid disorders occur at similar rates in T-cell compromised, HIV positive individuals<sup>29,30</sup>. But perhaps even more importantly, we found that rheumatoid arthritis as well as KCS, xerostomia, and periodontitis were all found to implicate individuals with a genetic disposition for the HLA-DR and/or its associated HLA-DQ subtypes of MHC II molecules<sup>3,4,18,19,23,28</sup>. In particular, HLA-DRB1 and HLA-DR4 associations were particularly prevalent, with the destruction of alveolar and carpal bones dose-dependent upon the expression of HLA-DRB1. Though the matter may require further investigation, research so far reinforces a significant comorbidity between RA and cases of KCS, xerostomia, and periodontitis. Perhaps not surprisingly, the molecular motif between these publications seems to be a fault in B cell-MHC II interactions.

Regardless of the exact molecular mechanism, the trends seen in RA and maxillofacial conditions is notable and best utilized to increase the degree of cooperation between lower limb specialists and other healthcare practitioners. Non-podiatrists must realize the significance of conditions like periodontitis in RA and consider pre-emptive referrals to lower limb specialists. Podiatrists, on the other hand, should be well aware of the extra-rheumatic symptoms of RA to organize a model of combined care, so that any RA patients they may see are also encouraged to seek regular dental and optometric treatments. A significant interprofessional alliance may be required to address not only the musculoskeletal issues but also the facial pathology that may arise as a result of the autoimmune processes.

### **Pharmacologic Relevance**

The implications of distal, maxillofacial pathology in foot and ankle rheumatoid arthritis also have a bearing in its pharmacologic treatment rendered by the podiatrist. Fundamentally, disease-modifying antirheumatic drugs (DMARDs) are regarded the best course of treatment for arresting the autoimmune component of RA. DMARDs encompass different classes such as calcineurin inhibitors, purine metabolism inhibitors, pyrimidine synthesis

inhibitors, and apoptosis inducers<sup>31,32</sup>. Though these medications cannot fully cure RA, they are often successful in slowing its progression and contributing to patient quality of life<sup>5,33</sup>.

Because of their system-wide mechanisms of action, DMARDs cause several unwanted side effects in the maxillofacial region. Agents such as methotrexate – a purine metabolism inhibitor – are known to cause severe ulcerations of the oral mucosa while ciclosporin – a calcineurin inhibitor – has been implicated with unwarranted gingival expansion<sup>33–35</sup>. In RA patients with salivary deficiencies, oral ulceration and inflammation may be unusually difficult diseases as saliva plays a critical role in mucosal defense as well as wound healing<sup>36–38</sup>. In addition, chloroquines – which are apoptosis inducers – have been shown to cause ocular damage which may prove to be especially detrimental to KCS sufferers of the RA patient pool<sup>39</sup>. In light of the prevalence of ocular and oral manifestations of RA, podiatrists and podiatric rheumatologists must take care when prescribing medications that may adversely affect the patient's maxillofacial conditions. Furthermore, additional research is required to determine the exact extent of antirheumatic medications that may incur side effects within the head and neck region.

### **Discussions**

#### *A Public Health Model*

There is little doubt that rheumatoid arthritis is a harrowing issue for many podiatric patients worldwide, especially because of the burden of RA on the lower limbs. Moreover, though centers of podiatric medicine should be the ultimate providers of lower limb RA care, it is also important to understand that most patients do not approach such institutions until they have become significantly immobile. To better address this issue, local pharmacies as well as dental and optometric clinics may be utilized as the first-lines of screening for RA. Simple, affordable, and rapid diagnostic tests are widely available that can detect the presence of KCS, xerostomia, or periodontitis at even rural pharmacies or clinics – KCS and xerostomia can be detected by measuring the volume of glandular secretions, while periodontitis can be detected by measuring the

recession of the oral mucosa. Individuals who are found to have one or more RA-linked conditions can then be transferred to undergo detailed evaluations by a podiatric physician, who will address these issues comprehensively. Because most insurance regimens already include a dental visit every six months and an optometric visit every twelve months, insurance agents can help ensure that the patients are screened regularly. However, without a new generation of podiatrists willing to provide education to their fellow healthcare colleagues, rheumatoid arthritis may continue to evade early detection and remain a debilitating pathology of the lower limbs in the foreseeable future.

### *Other Implications*

Our model of RA detection via maxillofacial markers and the proposed public health measures may also be utilized to detect other high risk pathologies of the lower limbs in the future. For example, early indicators of diabetes and diabetic neuropathy – such as mucosal changes - are well known to manifest in the oral cavity<sup>40,41</sup> as well as in the eyes<sup>42</sup>, providing potential diagnostic opportunities. In addition, saliva has been proposed as an accessible, non-invasive diagnostic modality for gout<sup>43</sup> and generalized hyperurecemia,<sup>44</sup> even before symptoms of metatarsal-phalangeal pain become apparent. As inlets for the central nervous and gastrointestinal systems, the eyes and the mouth (respectively) are exciting potential view points for a peek into the general health of the bodily extremities

Further research is required to ascertain the exact mechanism through which RA specifically initiates the destructive processes in the lacrimal, salivary, and alveolar tissues. Investigators may choose to explore interactions between B cells and HLA-DRB1 up-regulated chondrocytes in vitro, or to utilize animal models of HLA-DRB1 positive and B cell-negative individuals. However, it is in the authors' opinion that sufficient epidemiological data exists to trial the utilization of the pharmacy, dental, and optometric visits for early diagnosis of lower limb RA. The potential downfalls of advanced rheumatoid arthritis heavily outweigh the small inconveniences of regular community screenings. Furthermore, the establishment of pharmacy, dental, and optometric

protocols for detecting RA can later be applied to the detection of a broader number of pathologies in podiatry as such methods are explored further.

### **Resources**

1. Helmick, C. G. et al. Estimates of the prevalence of arthritis and other rheumatic conditions in the United States. Part I. *Arthritis Rheum.* 58, 15–25 (2008).
2. Edwards, J. C., Cambridge, G. & Abrahams, V. M. Do self-perpetuating B lymphocytes drive human autoimmune disease? *Immunology* 97, 188–96 (1999).
3. Plenge, R. M. et al. TRAF1–C5 as a Risk Locus for Rheumatoid Arthritis — A Genomewide Study. *N. Engl. J. Med.* 357, 1199–1209 (2007).
4. Soory, M. Association of periodontitis with rheumatoid arthritis and atherosclerosis: Novel paradigms in etiopathogenesis and management? *Open Access Rheumatol. Res. Rev.* 2, 1–16 (2010).
5. Majithia, V. & Geraci, S. A. Rheumatoid Arthritis: Diagnosis and Management. *Am. J. Med.* 120, 936–939 (2014).
6. Michelson, J., Easley, M., Wigley, F. M. & Hellmann, D. Foot and Ankle Problems in Rheumatoid Arthritis. *Foot Ankle Int.* 15, 608–613 (1994).
7. Cimino, W. G. & O'Malley, M. J. RHEUMATOID ARTHRITIS OF THE ANKLE AND HINDFOOT. *Rheum. Dis. Clin.* 24, 157–172 (2014).
8. Otter, S. J. et al. Foot pain in rheumatoid arthritis prevalence, risk factors and management: an epidemiological study. *Clin. Rheumatol.* 29, 255–71 (2010).
9. Turner, D. E., Helliwell, P. S., Emery, P. & Woodburn, J. The impact of rheumatoid arthritis on foot function in the early stages of disease: a clinical case series. *BMC Musculoskelet. Disord.* 7, 102 (2006).
10. Saag, K. G. et al. American College of Rheumatology 2008 recommendations for the use of nonbiologic and biologic disease-modifying antirheumatic drugs in rheumatoid arthritis. *Arthritis Rheum.* 59, 762–84 (2008).
11. Van der Heijde, D. M. F. M. Plain X-rays in rheumatoid arthritis: overview of scoring methods, their reliability and applicability. *Baillieres. Clin. Rheumatol.* 10, 435–453 (1996).
12. Nishimura, K. et al. Meta-analysis: Diagnostic Accuracy of Anti-Cyclic Citrullinated Peptide Antibody and Rheumatoid Factor for Rheumatoid Arthritis. *Ann. Intern. Med.* 146, 797–808 (2007).
13. Kaur, S., White, S. & Bartold, P. M. Periodontal disease and rheumatoid arthritis: a systematic review. *J. Dent. Res.* 92, 399–408 (2013).

14. Koziel, J., Mydel, P. & Potempa, J. The link between periodontal disease and rheumatoid arthritis: an updated review. *Curr. Rheumatol. Rep.* 16, 408 (2014).
15. Mody, G. M., Hill, J. C. & Meyers, O. L. Keratoconjunctivitis sicca in rheumatoid arthritis. *Clin. Rheumatol.* 7, 237–241 (1988).
16. Thompson, M. & Eadie, S. Kerato-conjunctivitis sicca and rheumatoid arthritis. *Ann. Rheum. Dis.* 15, 21–5 (1956).
17. Zlatanovi, G. & Paovi, A. S. KERATOCONJUNCTIVITIS SICCA IN PATIENTS WITH RHEUMATOID ARTHRITIS. 4, 48–50 (1997).
18. Liu, K. C., Huynh, K., Grubbs, J. & Davis, R. M. Autoimmunity in the pathogenesis and treatment of keratoconjunctivitis sicca. *Curr. Allergy Asthma Rep.* 14, 403 (2014).
19. HASSAN, W. U., KEANEY, N. P., HOLLAND, C. D. & KELLY, C. A. Association of HLA-DR4, protease inhibitor phenotypes and keratoconjunctivitis sicca with pulmonary anomalies in rheumatoid arthritis. *Rheumatology* 34, 37–40 (1995).
20. Nederfors, T. Xerostomia and Hyposalivation. *Adv. Dent. Res.* 14, 48–56 (2000).
21. Petrone, D. et al. A double-blind, randomized, placebo-controlled study of cevimeline in Sjögren's syndrome patients with xerostomia and keratoconjunctivitis sicca. *Arthritis Rheum.* 46, 748–54 (2002).
22. RUSSELL, S. L. & REISINE, S. INVESTIGATION OF XEROSTOMIA IN PATIENTS WITH RHEUMATOID ARTHRITIS. *J. Am. Dent. Assoc.* 129, 733–739 (1998).
23. Hansen, A., Lipsky, P. & Dörner, T. New concepts in the pathogenesis of Sjogren syndrome: many questions, fewer answers. *Curr. Opin. Rheumatol.* 563–570 (2003). at <[http://journals.lww.com/co-rheumatology/Abstract/2003/09000/New\\_concepts\\_in\\_the\\_pathogenesis\\_of\\_Sjogren.7.aspx](http://journals.lww.com/co-rheumatology/Abstract/2003/09000/New_concepts_in_the_pathogenesis_of_Sjogren.7.aspx)>
24. Savage, A., Eaton, K. a, Moles, D. R. & Needleman, I. A systematic review of definitions of periodontitis and methods that have been used to identify this disease. *J. Clin. Periodontol.* 36, 458–67 (2009).
25. Taubman, M. a, Valverde, P., Han, X. & Kawai, T. Immune response: the key to bone resorption in periodontal disease. *J. Periodontol.* 76, 2033–41 (2005).
26. Pischon, N. et al. Association among rheumatoid arthritis, oral hygiene, and periodontitis. *J. Periodontol.* 79, 979–86 (2008).
27. Ramamurthy, N. S., Greenwald, R. a, Celiker, M. Y. & Shi, E. Y. Experimental arthritis in rats induces biomarkers of periodontitis which are ameliorated by gene therapy with tissue inhibitor of matrix metalloproteinases. *J. Periodontol.* 76, 229–33 (2005).
28. Marotte, H. et al. The association between periodontal disease and joint destruction in rheumatoid arthritis extends the link between the HLA-DR shared epitope and severity of bone destruction. *Ann. Rheum. Dis.* 65, 905–9 (2006).
29. Kole, A., Kole, D. & Roy, R. Musculoskeletal and rheumatological disorders in HIV infection: Experience in a tertiary referral center. *Indian J. Sex. Transm. Dis. AIDS* 34, 107–112 (2013).
30. Yang, J.-J. et al. Autoimmune diseases-related arthritis in HIV-infected patients in the era of highly active antiretroviral therapy. *J. Microbiol. Immunol. Infect.* 1–7 (2013). doi:10.1016/j.jmii.2013.08.002
31. Smolen, J. S., van der Heijde, D., Machold, K. P., Aletaha, D. & Landewé, R. Proposal for a new nomenclature of disease-modifying antirheumatic drugs. *Ann. Rheum. Dis.* 73 , 3–5 (2014).
32. Nandi, P., Kingsley, G. H. & Scott, D. L. Disease-modifying antirheumatic drugs other than methotrexate in rheumatoid arthritis and seronegative arthritis. *Curr. Opin. Rheumatol.* 20, (2008).
33. Troeltzsch, M. et al. Oral mucositis in patients receiving low-dose methotrexate therapy for rheumatoid arthritis: report of 2 cases and literature review. *Oral Surg. Oral Med. Oral Pathol. Oral Radiol.* 115, e28–33 (2013).
34. Kalantzis, A., Marshman, Z., Falconer, D. T., Morgan, P. R. & Odell, E. W. Oral effects of low-dose methotrexate treatment. *Oral Surg. Oral Med. Oral Pathol. Oral Radiol. Endod.* 100, 52–62 (2005).
35. Naesens, M., Kuypers, D. R. J. & Sarwal, M. Calcineurin inhibitor nephrotoxicity. *Clin. J. Am. Soc. Nephrol.* 4, 481–508 (2009).
36. Tenovuo, J. et al. Antimicrobial Agents in Saliva—Protection for the Whole Body. *J. Dent. Res.* 81 , 807–809 (2002).
37. Umeki, H. et al. Leptin promotes wound healing in the oral mucosa. *PLoS One* 9, e101984 (2014).
38. Oudhoff, M. J. et al. Histatins are the major wound-closure stimulating factors in human saliva as identified in a cell culture assay. *FASEB J.* 22, 3805–12 (2008).

39. Michaelides, M., NB, S., PJ, F. & RG, W. Retinal toxicity associated with hydroxychloroquine and chloroquine: Risk factors, screening, and progression despite cessation of therapy. *Arch. Ophthalmol.* 129, 30–39 (2011).
40. Sykes, L. M. & Sukha, A. Potential risk of serious oral infections in the diabetic patient: A clinical report. *J. Prosthet. Dent.* 86, 569–573 (2001).
41. Shenoy, M. et al. A comparative study of oral candidal species carriage in patients with type1 and type2 diabetes mellitus. *J. Oral Maxillofac. Pathol.* 18, 60–65 (2014).
42. Calvo-Maroto, A. M., Perez-Cambrodi, R. J., Albaran-Diego, C., Pons, A. & Cervino, A. Optical quality of the diabetic eye: a review. *Eye* 28, 1271–1280 (2014).
43. Guan, Y., Chu, Q. & Ye, J. Determination of uric acid in human saliva by capillary electrophoresis with electrochemical detection: potential application in fast diagnosis of gout. *Anal. Bioanal. Chem.* 380, 913–917 (2004).
44. Inoue, K., Namiki, T., Iwasaki, Y., Yoshimura, Y. & Nakazawa, H. Determination of uric acid in human saliva by high-performance liquid chromatography with amperometric electrochemical detection. *J. Chromatogr. B* 785, 57–63 (2003).

# A Biochemical Review of Charcot Neuroarthropathy and Treatment Options

Alex Dawoodian, MS4 · Western University of Health Sciences College of Podiatric Medicine

## Introduction

Long standing peripheral neuropathy from chronic diabetes can ultimately result in Charcot neuroarthropathy, a debilitating disease that primarily affects bones, joints, and soft tissue. It is commonly associated with diabetic patients with peripheral neuropathy. There are several theories that possibly explain the pathophysiology, these include: 1) Neurotrophic: degenerative changes to the CNS lead to neurogenic loss of osseous nutrition allowing for the arthritic process 2) Neurovascular: radiographic evidence of osteolysis in patients with spinal cord injury supported a CNS failure causing a hypervascular reflex leading to bone resorption and mechanical weakening of the bone strength, initiating the Charcot destruction 3) Neurotraumatic: repetitive microtrauma from weight bearing on the insensate joint(s) results in instability, subluxation/dislocation, and osseous destruction. Typically, the hallmark sign of an advanced Charcot neuroarthropathy patient is a midfoot collapse or a “rocker-bottom” deformity. Eventually, as the midfoot collapses this creates bony prominences on the plantar aspect of the foot that can result in ulcerations.<sup>1</sup>

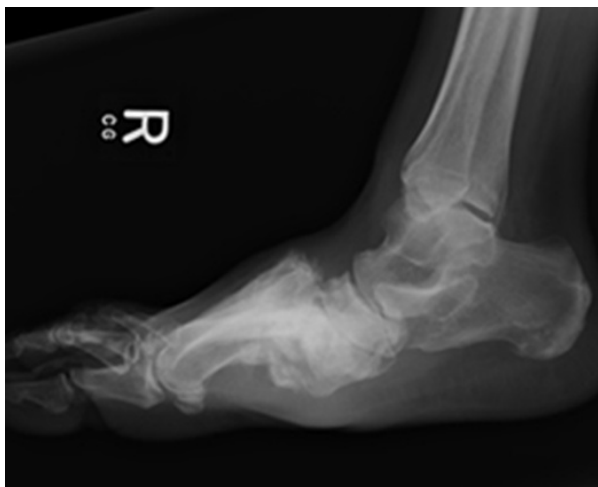

Figure 1: X-ray image of boney destruction from a Charcot event

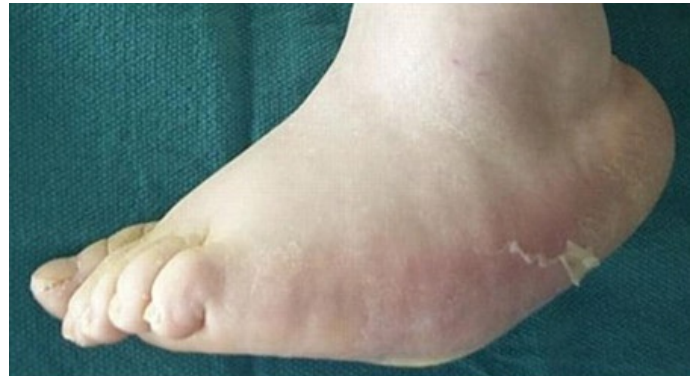

Figure 2: Clinical image of foot deformity due to Charcot

## Pathogenesis

Although the pathophysiology is still unclear there has been more insight discovered with the biochemical pathway, thus researchers are obtaining a deeper understanding of how lytic bone is manifested through this disease. It appears that inflammation is a common theme between many multifaceted pathways. Diabetic patients are in a state of inflammation and as a result, there is an unbalanced synergy between osteoblast and osteoclast, favoring the latter. Moreover, there is an increased production of cytokines, TNF- $\alpha$ , IL-1, and IL-6. As these factors are up regulated it leads to osteoclast differentiation.<sup>2</sup>

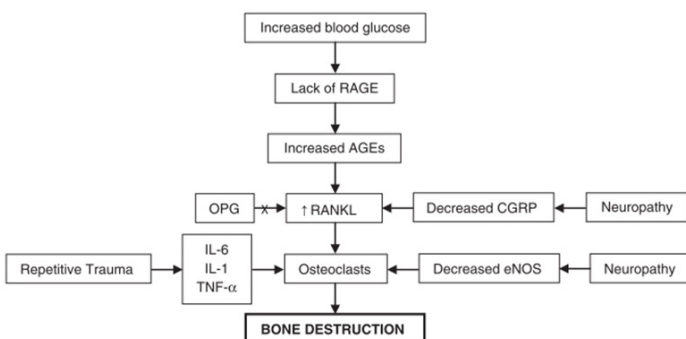
There exists an independent RANKL pathway that was noted in Charcot patients. Typically, there is an interaction between receptor activator nuclear factor-kappa ligand (RANKL) and its receptor RANK. Once the ligand binds to the receptor the nuclear factor NF- $\kappa\beta$  is released within the nucleus to begin differentiation of osteoclasts. The inhibitory protein involved in the pathway is osteoprotegerin (OPG). It was suggested that disruption of the OPG and RANKL interaction leads to vascular smooth muscles calcification and the radiographic signs of osteopenia.<sup>3,4</sup>

As inflammation induces RA=NKL, calcitonin gene-related peptide (CGRP) is normally there to antagonize this pathway inhibiting osteoclast



differentiation. Peripheral neuropathy as a result from diabetes inhibits CGRP release, thus allowing RANKL to carry on its activity. CGRP is created in the hypothalamus and is ultimately found on the periosteum and bone marrow. In cases of Charcot neuroarthropathy it was noted that there are low levels of CGRP.<sup>5,6</sup> In addition to the neuropeptide CGRP, there is isoenzyme endothelial nitric oxide synthase (eNOS) which is responsible for regulating nitric oxide levels. Nitric oxide, exists as a free radical due to the nature of its compound, and because of its highly reactive state it can interrupt osteoclast differentiation. When examining osteolytic bone of Charcot neuroarthropathy, it was found to have a decreased level of eNOS thus showing another perspective of osteoclasts being uninhibited.<sup>7</sup>

Often diabetes goes hand in hand with the development of Charcot neuroarthropathy. Typically with diabetics they are in a hyperglycemic state and that can offset the osteoblast and osteoclast balance. Elevated sugars facilitate the accumulation of advanced glycation end products (AGE). AGE products stimulate RANKL activity thus potentiating more osteoclast differentiation. Normally AGE products are taken up by receptor of advanced glycation end products (RAGE), but when there is copious amounts in circulation there are not enough receptors to balance out the increased AGE products.<sup>8</sup>

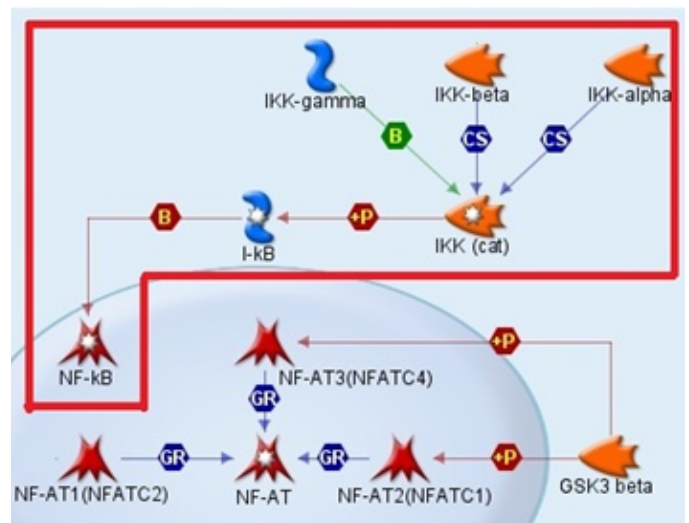


**Figure 3:** Depicting the interrelated pathways that lead to osteoclast differentiation and bone destruction

### IKK Pathway

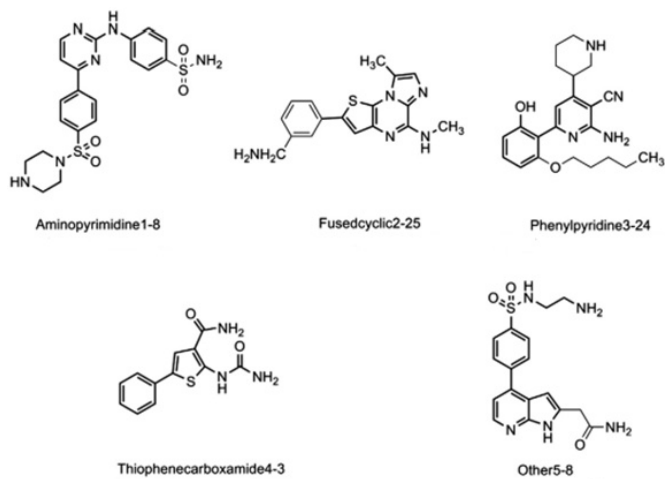
The transcription factor NF- $\kappa$ B is combined with I $\kappa$ B inhibitors which by in large is withheld in the cytoplasm. When the cells are exposed to pro-inflammatory cytokines such as TNF- $\alpha$ , IL-1, or bacterial LPS; the I $\kappa$ B's are phosphorylated which leads to ubiquitination and ultimately degradation. At

this point the NF- $\kappa$ B is released from its complex and now can be localized into the nucleus and targets DNA to activate specific genetic sequences for osteoclast differentiation. The important component that is responsible for the phosphorylation is a kinase enzyme known as IKK, which is composed of three subtypes: IKK $\alpha$ , IKK $\beta$ , and IKK $\gamma$ . IKK $\alpha$  and IKK $\beta$  are relatively similar in structure and both phosphorylate I $\kappa$ B at the NH<sub>2</sub>-regulatory NH<sub>2</sub>-terminal regulatory serines, whereas IKK $\gamma$  acts as a regulatory enzyme in the phosphorylation process. Interestingly, studies showed that IKK $\beta$  plays a critical role in the activation of NF- $\kappa$ B. Gene knockout experiments showed that when IKK $\alpha$  was knocked out the pathway was still able to carry out its I $\kappa$ B degradation to release NF- $\kappa$ B, however when IKK $\beta$  was knocked out there was a severe defect in activation of NF- $\kappa$ B.<sup>9</sup> Therefore further studies on therapeutic agents are geared towards targeting IKK $\beta$ .



**Figure 4:** focusing on the IKK dependent pathway

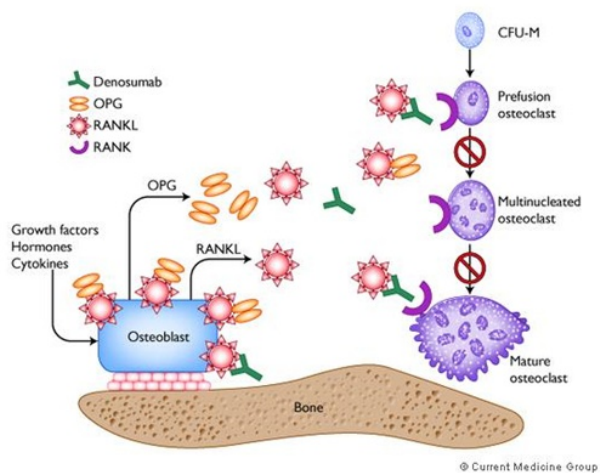
Huang et al. used virtual screening which utilized the co-crystal structure of IKK $\beta$  and various inhibitors in a high through put screening process. After repeated docking sessions into the IKK $\beta$  crystal structure they noted five different pharmacophore compounds to have the highest affinity for the binding pocket of IKK $\beta$ . The compounds listed are as follows: 1) aminopyrimidine 2) fused cyclic 3) phenylpyridine 4) thiophenecarboxamide 5) other. The images of these structures can be viewed below.<sup>10</sup>



**Figure 5:** Depicting the chemical structure of the five pharmacophores that displayed high affinity for IKKβ

### Antiresorptive agents

Advances in pharmaceutical agents have shown that there are monoclonal antibodies that can potentially interrupt the RANK/RANKL pathway. The first FDA approved human monoclonal antibody that is able to inhibit RANKL is known as denosumab. It is highly specific and highly capable of interfering with the RANKL pathway, which ultimately prevents maturation, differentiation, and fusion of mononuclear osteoclast precursors to form multinucleate osteoclasts.<sup>11</sup>



**Figure 6:** Portrays the effects of denosumab in the RANK/RANKL pathway and how it is pharmacologically

A study was done comparing a placebo group and a patient population treated with zoledronic acid and off-loading, over a 6 month period. The results showed that bone mineral density significantly increased with the treated group compared to the

placebo group.<sup>12</sup> Other literature cite that even though bisphosphonates can decrease bone turnover there is no demonstrable data that shows it can delay further bone deformities.<sup>13</sup> The use of bisphosphonates still remains inconclusive as there aren't many studies done to show follow up data.

### Treatment Options

Current standard of conservative treatment for active Charcot neuroarthropathy is offloading the foot and/or immobilization. The main goal with this treatment modality is to prevent further bone destruction from weight bearing activities. Once an active episode subsides, it is strongly recommended for the patient to wear protective devices such as prescription shoes, boots, or braces. Since this disease is related to diabetes it must be followed lifelong as the patient not only has to monitor blood sugar and A1c levels, but must also examine his or her feet and be keen on any signs of recurrence.

Furthermore, if conservative treatment options fail then surgery is the next step for patients. The goal in mind is to remove bony prominences due to deformities so that pressure is relieved to help alleviate pressure ulcers. Soft tissue procedures may include lengthening of the Achilles tendon or gastrocnemius tendon. These procedures would allow relief of forefoot pressure and improve the alignment of the ankle along with the hind foot. If instability progresses and bone remains intact, an arthrodesis can be useful to alleviate pain or recurrent ulcerations that have failed with non-operative treatments and to provide more stability.<sup>14</sup>

### Conclusion

Charcot neuroarthropathy is a multifaceted complication of diabetes and peripheral neuropathy that requires a lifelong surveillance. As more understanding has been gained through research, the knowledge can be used to combat the problem in a biochemical perspective. Since inflammation is the major causative agent that promulgates complex pathways leading to bone destruction, it is at this epicenter that drives researchers and drug companies to devise innovative approaches to combat this disorder. With the computational technology available it is possible to utilize FDA approved drugs

and possibly repurpose these compounds for combating Charcot neuroarthropathy. As time progresses and treatment options become more refined it will be a tremendous goal for detecting Charcot neuroarthropathy early on and preventing bone destruction.

## References:

1. Sanders LJ. The Charcot foot: Historical perspective 1827-2003. *Diabetes Met Res & Review*, 2004: S4-S8
2. Baumhauer JF, O'Keefe RJ, Schon LC, Pinzur MS. Cytokine-induced osteoclastic bone resorption in Charcot arthropathy: an immunohistochemical study. *Foot Ankle Int* 2006; 27: 797-800
3. Jeffcoate W. Vascular calcification and osteolysis in diabetic neuropathy\*is RANK-L the missing link? *Diabetologia* 2004; 47: 1488-92.
4. Mabileau G, Petrova NL, Edmonds ME. Increased osteoclastic activity in acute Charcot's osteoarthropathy: the role of receptor activator of nuclear factor-kappaB ligand. *Diabetologia* 2008; 51: 1035-40
5. Akopian A, Demulder A, Ouriagli F, Corazza F, Fondou P, Bergmann P. Effects of CGRP on human osteoclast-like cell formation: a possible connection with the bone loss in neurological disorders? *Peptides* 2000; 21: 559-64.
6. Irie K, Hara-Irie F, Ozawa H, Yajima T. Calcitonin gene-related peptide (CGRP)-containing nerve fibers in bone tissue and their involvement in bone remodeling. *Microsc Res Tech* 2002; 58: 85-90.
7. La Fontaine J, Harkless LB, Sylvia VL, Carnes D, Heim-Hall J, Jude E. Levels of endothelial nitric oxide synthase and calcitonin gene-related peptide in the Charcot foot: a pilot study. *J Foot Ankle Surg* 2008; 47: 424-9.
8. Witzke KA, Vinik AI, Grant LM, Grant WP, Parson HK, Pittenger GL, et al. Loss of RAGE defense: a cause of neuroarthropathy? *Diabetes Care* 2011; 34: 1617-21.
9. Zhi-Wei Li, Wenming Chu, Yinling Hu, Mireille Delhase, Tom Deerinck, Mark Ellisman, Randall Johnson, and Michael Karin. The IKK b Subunit of Ikb Kinase (IKK) is Essential for Nuclear Factor kb Activation and Prevention of Apoptosis. *Journal Exp. Med.* Volume 189, Number 11, June 7, 1999, 1839-1845
10. Jing-Jie Huang, Xiao-Wen Wu, Jian-Min Jia, Xiao-Ke Guo, Xin Xue, Zheng-Yu Jiang, Sheng-Lie Zhang, Xiao-Jin Zhang, Hao-Peng Sun, Qi-Dong You. Novel IKK b inhibitors discovery based on the co-crystal structure by using binding-conformation-based and ligand-based

method. *European Journal of Medicinal Chemistry*, 63 (2013) 269-278

11. Natalie A. Sims & Kong Wah Ng. Implications of Osteoblast-Osteoclast Interactions in the Management of Osteoporosis by Antiresorptive Agents Denosumab and Odanacatib. *Curr Osteoporos Rep.* Jan 30, 2014
12. Pakarinen TK, Laine HJ, Mäenpää H, Kähönen M, Mattila P, Lahtela J. Effect of immobilization, off-loading and zoledronic acid on bone mineral density in patients with acute Charcot neuroarthropathy: a prospective randomized trial. *Foot Ankle Surg.* 2013 Jun;19(2):121-4.
13. Pakarinen TK, Laine HJ, Mäenpää H, Mattila P, Lahtela J. The effect of zoledronic acid on the clinical resolution of Charcot neuroarthropathy: a pilot randomized controlled trial. *Diabetes Care.* 2011 Jul;34(7):1514-6
14. Rogers LC, Frykberg RG, Armstrong DG, Boulton AJM, et al. The Charcot Foot in Diabetes. *J Am Podiatr Med Assoc* 101(5): 437-446, 2011

Fig 1: <http://www.apcofamerica.com/wp-content/uploads/2014/11/e800bf7367b7375f3bdcb6228aa5a3be.jpg>

Fig 2: [http://bestpractice.bmj.com/best-practice/images/bp/en-gb/531-7\\_default.jpg](http://bestpractice.bmj.com/best-practice/images/bp/en-gb/531-7_default.jpg)

Fig 3: Shelly A. M. Larson, DPM and Patrick R. Burns, DPM. The pathogenesis of Charcot neuroarthropathy: current concepts. *Diabetic Foot & Ankle*, 2012: 1-4

Fig 4: <http://pathwaymaps.com/maps/620/>

Fig 5: Jing-Jie Huang, Xiao-Wen Wu, Jian-Min Jia, Xiao-Ke Guo, Xin Xue, Zheng-Yu Jiang, Sheng-Lie Zhang, Xiao-Jin Zhang, Hao-Peng Sun, Qi-Dong You. Novel IKK b inhibitors discovery based on the co-crystal structure by using binding-conformation-based and ligand-based method. *European Journal of Medicinal Chemistry*, 63 (2013) 269-278

Fig 6: (extras.springer.com)

<http://www.google.com/url?sa=i&rct=j&q=&esrc=s&source=images&cd=&docid=Y0WB0eZgFbYR4M&tbnid=aYNL7Uvyqg7CkM:&ved=0CAQQjB0&url=http%3A%2F%2Fextras.springer.com%2F2009%2F978-1-57340-296-5%2F01%2F0118%2F0118014LA.html&ei=DfL3UuZSiPWgBI-8gvAO&bvm=bv.60983673,d.cGU&psig=AFQjCNHLo19oXsLLxKTxRtBuZOcUwEBIw&ust=1392067465585886>

# Evolution of Treatment: The New Frontier of DVT Therapy

Mia Amanda Laurel, OMS-IV · Western University of Health Sciences, College of Osteopathic Medicine of the Pacific

## Abstract for case report

61-year-old male with no prior history of venous thromboembolism presents with one-week history of painful swollen leg and new onset stabbing, pleuritic chest pain. Extensive proximal to distal deep vein thrombosis and secondary pulmonary embolus is diagnosed with Doppler and CT angiogram, respectively. How should the deep vein thrombosis be treated?

## Case presentation

This 61-year-old mildly obese male previously presented to a different hospital complaining of a swollen left leg and progressive, unremitting pain. Patient was positive for a three-week history of decreased activity level due to recent pneumonia. He also had left sided calf swelling extended proximally over the next several days. Venous duplex confirmed extensive clotting within the iliac and femoral veins of the left lower extremity. Systemic anticoagulation was initiated and he was discharged on Enoxaparin 120mg twice daily and daily Coumadin 10mg.

The following morning the patient was brought to our emergency department with complaints of severe stabbing left sided chest pain. He denied shortness of breath or palpitations. On physical exam he was found to have left leg swelling and a positive Homan's sign. CT angiogram confirmed three pulmonary emboli despite an INR of 3.9.

Vascular surgery was consulted and recommended catheter directed fibrinolytic therapy for treatment of the extensive thrombosis in his left lower extremity.

Initial venogram of the left lower extremity confirmed diffuse thrombus throughout the popliteal superficial femoral vein, common femoral vein, and distal external iliac vein. There was no thrombus in the left common iliac vein or inferior vena cava. After the line was secured, 5 mg of alteplase was then

placed within the infusion catheter to lase the diffuse thrombus. The patient was cared for in the intensive care unit (ICU) overnight.

On the morning of the second procedure, sequential venograms revealed that all of the named vessels of the left extremity except for the external iliac contained a thrombus. An AngioJet catheter was utilized for mechanical thrombectomy of the residual thrombotic material from the left popliteal, superficial femoral, common femoral, and external iliac venous segments. Further proximal exploration revealed 80% occlusive block by thrombus in the left common iliac. The clot was asymmetrically lucent and remained within the central aspect of the lumen after mechanical thrombectomy. Additionally, venocavogram revealed residual left common iliac venous luminal stenosis of approximately 40% suspicious for May-Thurner's syndrome.

May-Thurner syndrome is venous scarring within the lumen of the vessel that results from repeated irritation where the right common iliac artery passes over the left common iliac vein in the groin, pinning the structure against the posterior vertebral body. Over time a spider web of tissue builds up within the lumen causing narrowing and predisposition for deep vein thrombosis (DVT).

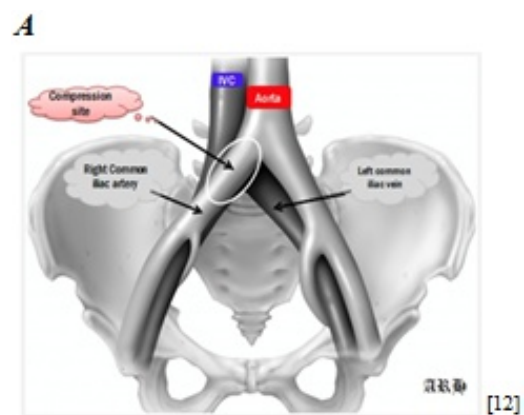
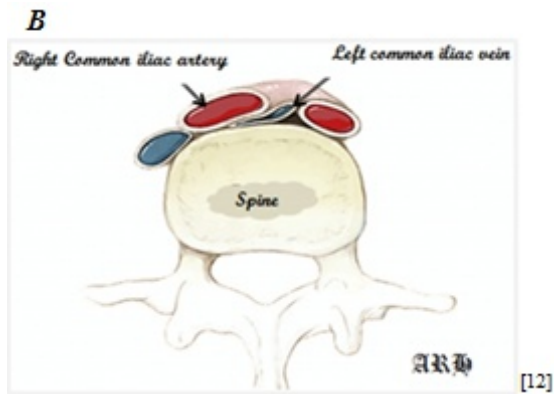


Figure A shows the pelvic anatomy and the right common iliac artery as it branches off the aorta and crosses the left



**Figure B** shows the same in cross section. It is postulated that the constant pulsations of the right iliac artery against the left iliac vein against the vertebral body are the source of the adhesions visible with IVUS

Given these findings and the residual clot in the left proximal iliac vein, a second day of catheter directed thrombolytic therapy was scheduled. The patient was returned to the ICU and scheduled for placement of an inferior vena caval (IVC) filter and intravascular ultrasound (IVUS) exploration of the lumen of the internal iliac vessel. Narrowing of the lumen would confirm May-Thurner syndrome, warranting a bilateral stent placement to prevent future recurrences of venous thromboembolism.

### Prevention of post-thrombotic syndrome

#### *Indications for fibrinolytics in the treatment of DVT*

Until recently, venous thromboembolism (VTE), a spectrum of disorders including both DVT and pulmonary embolism (PE), has not received much attention nationally. However, it represents the nation's leading cause of preventable hospital death, and a major cause of maternal mortality in the United States [11]. An estimated 300,000 - 600,000 individuals experience a VTE event each year [1] leading to approximately 100,000 deaths [2]. Furthermore, those patients that survive their encounter with VTE have a 23-60% chance of developing post thrombotic syndrome (PTS) within 1-5 years. [3]

PTS results from damage inflicted on the walls and valves of the vein during a thrombotic event. The pathological pressure leads to venous insufficiency and valvular destruction, ultimately creating venous hypertension. This underlying pathophysiology

presents as pain, venous dilation, edema, pigmentation, skin changes, and venous ulcers. Furthermore, PTS is the leading cause of venous insufficiency nationwide, and, in extreme cases, can become limb threatening. [5]

Proximal DVTs are especially dangerous. Approximately 80% of symptomatic DVTs are located above the knee. One study showed that 50% of patients with a proximal DVT would still experience PTS, despite appropriate therapy with long term anticoagulation and compression stockings. Of these, 10% would develop venous ulcers [1][10]. A second study found that DVT involving the iliofemoral venous segment would result in PTS over 67% of the time with 5% of patients suffering an ulceration [2].

For the sake of context, the economic impact of managing these well-known sequelae and its associated complications actually accounts for nearly 75% of the total cost of a DVT treatment, or \$300 million annually [2]. In the UK, the annual cost of managing venous ulcers alone is £400 million (approximately \$625 million USD)[4].

It should come as no surprise that prevention of PTS is desirable for both economic and humanitarian reasons. The mainstay treatment of DVT has been anticoagulant therapy, but recent attention has been given to the use of thrombolytics in conjunction with the conventional treatment as a means to reduce the occurrence of post thrombotic syndrome. Essential to prevention is preservation of valvular function, which seems to be directly related to early clot lysis[10]. While systemic anticoagulation stops clot propagation, it does not lyse existing clots and therefore does not relieve the pressure placed on the venous walls and valves.

Historically, systemic treatment with thrombolytic agents were considered first. These were found to result in unacceptably high bleeding rates in the initial trials with and complications such as retroperitoneal hematoma or intracranial hemorrhage systemically [5]. This led to the development of catheter directed thrombolysis (CDT). In CDT, a

catheter is threaded through the clot and thrombolytic medication is delivered directly to the body of the blood clot via small holes present along the length of the catheter. Depending on the size of the clot, a single dose of medicine delivered over the course of a couple hours may be the total treatment. Medications may also be given overnight, in combination with mechanical thrombectomy, or with an IVC filter. Initial data review suggests that combination therapies may result in increased risk of PE or other embolic event and that shorter duration of thrombolytic administration is preferable; however these did not account for the size of the clot or extent of the obstruction. [7]

While the procedure itself is relatively new to have sufficient data to fully elucidate the best possible practices for the many different variables; dose, duration, or combination therapies, the data is unified in that there is benefit in reducing post thrombotic syndrome (PTS). The risk benefit ratio is especially in favor of treating when considering the first time occurrence of a proximal DVT. [8]

In a small study involving 20 hospitals, 189 patients aged 18-75 with first time iliofemoral DVT were randomized into two treatment groups of conventional treatment alone or with additional CDT. Patients were followed for 24 months. There was a relative risk reduction of 14.4% in the development of post thrombotic syndrome. After 6 months iliofemoral patency was 65.9% in the CDT group vs. 47.4% in the control group. There were 20 bleeding complications related to CDT, three major and five clinically relevant[6][9].

Analysis of 12 different studies in the Cochran data base concluded that the long term advantages were significant including more complete removal of the clot, increased venous patency, and less PTS (RR 0.66; 95 % CI 0.47 to 0.94). Initially, the CDT group had significantly more bleeding incidents with a (RR 1.73; 95 % CI 1.04 to 2.88) including two strokes. However, as stricter eligibility criteria were adopted over time, complications became less common making the procedure “sufficiently safe and compelling.” [7]

There are currently no strict standards for when catheter directed agents should be used in conjunction with systemic anticoagulation [10]. While the incidence of PTS is decreased in patients undergoing CDT, there is still much debate about the safety of the procedure due to lack of standardization of the treatment and the varying degree of experience and resources available to local hospitals. With this taken into account, the American College of Chest Physicians issued the following guidelines in 2012[5]:

Patients who are most likely to benefit from CDT:

- ❖ Iliofemoral DVT
- ❖ Symptoms for <14 days
- ❖ Good functional status
- ❖ Life expectancy of  $\geq$  1 year
- ❖ Low risk of bleeding
- ❖ Appropriate expertise and resources available

In addition, due to the decreased bleeding risks, CDT is preferred over systemic thrombolysis and operative venous thrombectomy[5]. While mechanical fragmentation of the thrombus is encouraged as it can reduce the total dose required to achieve thrombolysis and thereby shorten the procedure, post-thrombotic thrombectomy of any remaining clot is discouraged as the rates of PE and other complications are high [5].

### Discussion

This patient was a candidate for thrombolytic therapy for the following reasons: this was a proximal clot occupying the femoral and popliteal veins, with a maturity less than 14 days old. The clot was highly symptomatic, both with three separate pulmonary emboli to the left lung as well as significant swelling and pain in the lower limb. Clinical estimate of patient life expectancy was greater than 1 year. Patient was without prior VTE events and no comorbid heart or vascular conditions, with no reason to expect anything except a return to health given successful intervention.

### Conclusion

Thrombolysis is an effective treatment option that both saves lives and improves long-term quality by decreasing PTS; however, it also carries the risk of significant and even fatal hemorrhagic events. While some of this risk remains even with the CDT

approach, the potential chronic morbidity of PTS provides incentive to consider early thrombolysis in carefully selected patients. It is the shared responsibility of both the clinician and the patient to weigh the risks and benefits of the procedure in the clinical decision-making. After a thorough review of the literature, our patient management matches with the current best-practice guidelines. We expect the best possible outcome for his recovery despite the extensive nature of his thromboembolic disease.

## References

1. Blum, A.S. (2006). Endovascular Management of Deep Vein Thrombosis. *Journal of Interventional Cardiology*, 19(5), S97-S101.
2. Beckman, M.G., Hooper, W.C., et al. (2010). Venous Thromboembolism: A Public Health Concern. *Am J Prev Med*, 38(4), S495-S501.
3. Ashrani, A.A., Heit, J.A. (2009). Incidence and cost burden of post-thrombotic syndrome. *J Thromb Thrombolysis*, 28(4), 465-476.
4. Patterson, B.O., Hinchliffe, R., Loftus, I.M. (2010). DVT: A New Era in Anticoagulant Therapy: Indications for Catheter-Directed Thrombolysis in the Management of Acute Proximal Deep Venous Thrombosis. *Arteriosclerosis, Thrombosis, and Vascular Biology*, 30(4), 669-674.
5. Akl, E.A., Kearon, C., et al. (2012). Antithrombotic Therapy for VTE Disease: Antithrombotic Therapy and Prevention of Thrombosis, 9th ed: American College of Chest Physicians Evidence-Based Clinical Practice Guidelines. *Chest*, 141(2), e419S-e494S.
6. Enden, T., Haig, Y., et al. (2012). Long-term outcome after additional catheter directed thrombolysis versus standard treatment for acute iliofemoral deep vein thrombosis (the CaVenT study): a randomized controlled trial. *Lancet*, 379(9810), 31-38.
7. Watson, L.I. and Armon, M.P. (2004). Thrombolysis for acute deep vein thrombosis. *Cochrane Database Syst Rev*, (4).
8. O’Riordan, M. (2011). Catheter-Directed Thrombolysis in Iliofemoral DVT Reduces Risk of Postthrombotic Syndrome. Retrieved from <http://www.medscape.com/viewarticle/755366> on 10 January 2014.
9. Hoffman, L.V., Kuo, W.T. (2012). Catheter-directed thrombolysis for acute DVT. *Lancet*, 379(9810), 3-4.

10. Kahn, S.R. (2010). The Post-Thrombotic Syndrome. *Hematology*, 2010(1), 216-220.
11. Berg, C.J., Callaghan, W.M. et al. (2010). Pregnancy-Related Mortality in the United States, 1998-2005. *Obstetrics and Gynecology*, 116(6), 1302-1309.
12. A Hamo, M Alyaseen, F Alkhankan, T Gress. Pulmonary Emboli without Leg Symptoms, May-Thurner syndrome. Case Report and Review. *Internet Scientific Publications*. Vol 9 N2, 2013

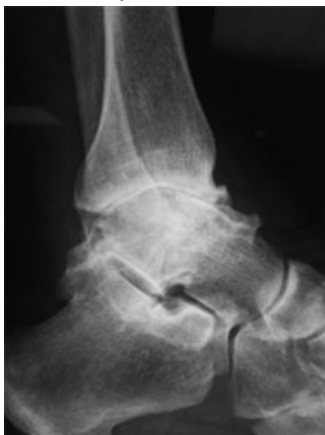# A Comparison in Gait and Other Parameters Following Treatment of Ankle Osteoarthritis with Tibio Talar Arthrodesis and Total Ankle Arthroplasty

Bryant Nachtigall MSIII · Western University of Health Sciences College of Podiatric Medicine

## Introduction

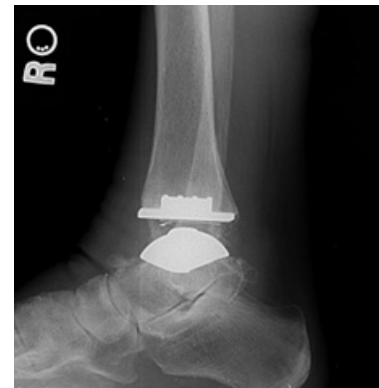In the most basic of terms, degenerative arthritis is the destruction of the articular cartilage lining a joint combined with the body's response to the resultant osseous contact. This destruction of articular cartilage of weight bearing joints constitutes a significant number of patient visits to specialists in musculoskeletal medicine. End stage ankle osteoarthritis (OA) is often associated with severe pain, a reduction in function to the lower extremity and the patient's well-being (1). Early recognition of ankle instability and risk factors for progression are critical to halting the disease progression. However, the treatment of the patient may require going beyond conservative care (NSAIDs, mechanical unloading, steroids) and joint preservation surgery for ankle OA.

Joint destruction surgical management of end stage ankle OA consists of primary tibiotalar arthrodesis and total ankle replacement (TAR). While ankle arthrodesis has historically been the surgical treatment of choice for ankle OA, recent advances and improved outcomes in 2nd generation TAR systems have made the TAR a viable option for the qualified patient (3,4). The decision to perform a TAR or arthrodesis is a well-thought out consideration of the following parameters: level of disease progression, patient's needs/expectations, age, comorbidities, alignment of the rear foot/distal leg, presence of ligamentous instability, or more distal foot deformity.



**Figure 1:** Lateral Ankle XR of Ankle OA. Note joint space narrowing, subchondral sclerosis and peri-talar formation of osteophytes

The progression of the disease and altered joint mechanics often alters the patient's gait and brings about significant impairments to the patients daily life. When discussing surgical treatment options the surgeon must be able to effectively predict and communicate to the patient the biomechanical effects of fusion verses arthroplasty. All else being equal, the differences in the patient's gait, functional ability, and potential for harmful sequela may dictate the course of surgical treatment. This article will be comparing the biomechanics and gait after TAR and ankle arthrodesis after a discussion regarding the etiology.



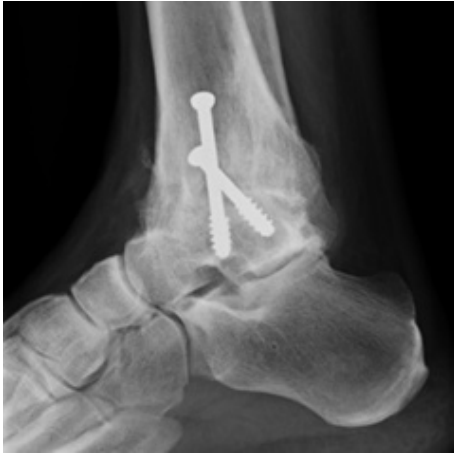**Figure 2:** STAR TAR

## Etiology

Current available information suggests knee OA is 8 to 10 times more common than ankle OA (5). Primary ankle OA is rare and currently post-traumatic arthritis resulting from ligamentous injury or ankle fractures is the most common cause of ankle OA. Current data suggests up to 70% of patients with ankle OA are from a post-traumatic origin (6). An epidemiologic study found that 79.5% of patients with ankle OA were verified to have a history of at least 1 joint injury (19). Saltzman and colleagues examined 639 patients presenting with end stage ankle OA and found rotational ankle fractures are the leading cause followed by ligamentous disruption (20). This data was confirmed by Valderrabano et al.



who evaluated 390 patients with end stage ankle OA. Valderrabano found 78% to have a posttraumatic origin with malleolar fractures (157 patients) followed by ligamentous disruption (60 patients) to be the most common reason for the degenerative changes (21). Other causes include septic arthritis, Rheumatoid, osteonecrosis of the talus, gout, and hemophilia (6).



**Figure 3:** Tibiotalar Arthrodesis

### **The Ankle's Resistance to Primary Ankle Osteoarthritis and Susceptibility to Post-Traumatic OA**

Some research has been done in order to investigate why the ankle has lower rates of primary OA compared to the knee and hip. Kempson conducted a study in which the tensile properties of the articular cartilage of the talus are compared to that of the femoral head. Early in life the femoral head has greater tensile fracture stress compared to the talus. However, as we age, the tensile fracture stress of the talus decreases at a slower rate compared to the femoral head (11). This contributes to the ankles' resistance to primary osteoarthritis and makes the ankle joint more resistant to cartilaginous insult as we age compared to the hip.

The susceptibility of the ankle to develop OA from traumatic events has been suggested to partly stem from the higher load the joint experiences in a smaller area compared to that of the knee and hip. Studies have shown that at 500N load the area of contact averages 350mm<sup>2</sup> in the ankle. Comparatively the knee and hip experience 1120mm<sup>2</sup> and 1100mm<sup>2</sup> respectively (7,8,9). The ankle articular cartilage is also thinner and has different tensile properties

compared to the articular cartilage of the knee and hip. The ankle articular cartilage has been found to range from slightly less than 1mm to slightly less than 2mm (9). The hip and knee enjoy more cushioning and protection as the articular cartilage can be as thick as 6mm providing more protection from osseous contact and development of OA (10).

Well-known and often cited original research projects have attempted to quantify the suspected level of instability of the mal-reduced posttraumatic ankle. According to Ramsey and Hamilton, with just 1mm of lateral talar shift the contact forces between the tibia and the talus may decrease up to 42%(22). Since the resulting contact stresses will increase with a decrease in total osseous joint contact this will cause uneven wear and accelerated degenerative joint changes. These findings have been confirmed by Lloyd et al. (23) and Zindrick et al (24).

These findings have not been met with universal acceptance. Ramsey and Hamilton, as well as Zindrick et al., used a highly constrained ankle model for conducting their experiments. The talus was fixed in the lateral displaced position and was not allowed to seek out its original position once load was applied. In the more likely in vivo situation of a laterally displaced talus the widened mortise simply creates the possibility of lateral displacement as opposed to a fixed lateral position. Pereira et al. sought to refute this evidence with a less constrained, more physiologic ankle model. Their results showed that even up to 4mm of lateral talar displacement the contact area was never reduced more than 2.5% with an intact deltoid (28). If the deltoid was ruptured they found up to a 19% decrease in total contact areas (28).

The take away from these studies is not the importance of determining the exact quantification of the decrease in joint surface contact following syndesmotic widening. But rather there exists a significant alteration in ankle biomechanics following ligamentous and osseous disruption in the ankle joint that accelerates degenerative changes. This only highlights the importance of appropriate identification of ligamentous and osseous injury to the ankle joint. Some have even suggested the use of ankle arthroscopy for the detection of syndesmotic injury(25). Lui prospectively studied 53 fractured

ankles with no preoperative evidence of syndesmotic reduction. The group discovered by intraoperative stress radiography that 30.2% of patients had a previously undetected unstable syndesmosis. Additionally, 66% of patients were found to have instability using ankle arthroscopy(26). With an average latency time of 20.9 years (27) until development of post-traumatic arthritis these points should cause us to place more emphasis to the potential life altering complications of ankle fractures and undetected ligamentous disruption.

### Biomechanics of the Arthritic Ankle

Clinical and biomechanical observation of the gait pattern in a patient with end stage ankle OA will reveal numerous abnormalities compared to a patient of the same age without ankle OA. Horisberger et al. measured plantar pressure distribution in a patient with ankle OA and discovered a significant decrease in maximum plantar force and contact area (12). Nuesch and Valderrabano examined 8 patients with end stage ankle OA using a 6 camera system combined with 2 force plates prior to the patients undergoing joint preservation surgery. The group was compared to 15 healthy controls with no history of pathology of the lower limb. They found the ankles with ankle OA had decreased ankle dorsiflexion, decreased peak ground reaction forces, and slowed walking speeds/cadence (13). The results of these studies suggest patients attempt to decrease the forces being transmitted through the ankle joint by decreasing the walking speed and force of each step in order to reduce pain.

### Gait and Other Parameters in an Ankle after TAR and Fusion

Queen, Biasio, and Butler et al. examined 51 patients at 1 and 2 years following TAR using modern 2nd generation fixed bearing prostheses (Inbone and Salto-Tolaris). The purpose was to appraise the changes in gait, functional outcomes, and patient reported functional outcomes of patients receiving a TAR for end stage ankle OA. VAS and AOFAS hindfoot score were used to calculate patient reported functional outcomes. The 4 square step test, timed get up and go, gait analysis using 8 camera motion analysis system, and ground reaction forces were all

used to evaluate the patients post-operatively. Overall the patients in both implant groups improved in nearly every category of gait mechanics (15). The improved performance of the timed get up and go test and four square test is proof that, at least in the short term, patients experience more stability and confidence in their ankles compared to their pre-operative ankles. One interesting take is the improvement in four square step test did not reach significance until the 2 year mark suggesting it may take a minimum of two years before a patient may feel confident ambulating in their implants.

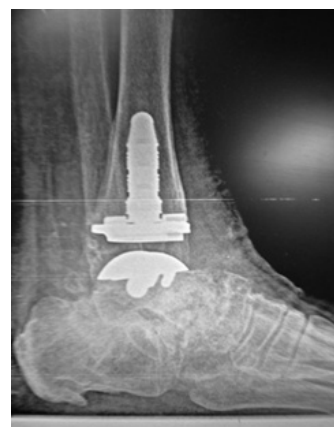

Figure 4: InBone TAR

Pain scores via the VAS and AOFAS score decreased significantly at both 1 and 2 years follow up. This decrease in pain and increase in stability/mobility, as indicated by the four square step test, resulted in patients spending less time in double limb support, more time in single limb support, and increased stride/step length compared to pre-op analysis. Ground reaction forces also increased significantly following TAR which indicates patients are more willing to accept force transmitted through the ankle during gait (13).

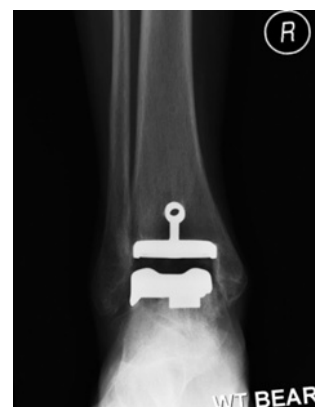
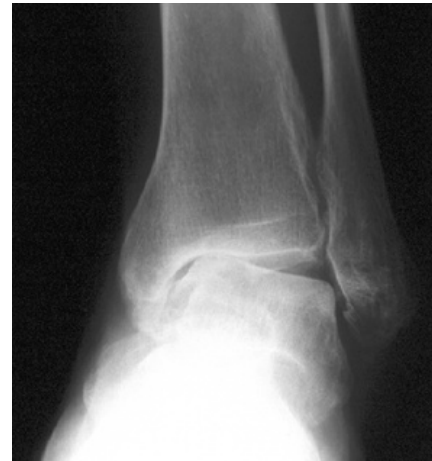
Figure 5: Salto-Tolaris TAR

Flavin and Coleman et al. compared 14 healthy volunteers and 28 patients with end stage ankle OA. Patients with ankle OA were split, with half receiving Tibiotalar arthrodesis and half receiving a STAR mobile bearing TAR (total ankle replacement). The decision was based on age, gender, and diagnosis. Patients were excluded from the TAR group if they were younger than 40 years old, had greater than 10 degrees of valgus/varus deformity in the coronal plane or if they requested a fusion. Healthy and post-op patients underwent testing for gait, temporospecial parameters, vertical ground reaction force (vGRF), and pedobarography pre-op and 1 year post-op. In terms of sagittal range of motion, the TAR group improved greater in dorsiflexion while the fusion group improved greater in planter flexion. Total sagittal range of motion in the TAR group was higher but failed to be significant at  $P=0.06$ . The authors suggest that this may be the result of peri-tibiotalar joint compensation pre-operatively, most likely at the talonavicular joint (14). Total coronal range of motion doubled in the TAR group but went unchanged in the fusion group. The authors contributed the greater amount of eversion to the mobile bearing nature of the STAR implant (14). VGRF pre-operatively showed similar values in both groups with similar improvements in this category in the TAR and fusion group (14).

According to the authors the most notable findings of their study was that the two treatment groups had similar outcomes. The TAR group was excluded from receiving an implant if a valgus/varus deformity existed in the ankle greater than 10 degrees. This means that ankles with end stage OA with a concomitant coronal plane deformity can be corrected with a fusion and achieve similar outcomes to a patient with a milder form of the disease receiving a TAR (at least in the short term) (14). Valgus/varus osteoarthritic ankles make the course of treatment more challenging to the surgeon and patient with some sources suggesting two stage procedures are required with an associated coronal plane deformity of over 10 degrees (18). Two stage procedures obviously entail a more lengthy treatment course necessitating two non-weight bearing time periods post-operatively. Bone stock proximal to the ankle also may not be amendable to coronal plane

correcting supramalleolar osteotomies due to systemic conditions, previous orthopedic surgeries, or trauma. These factors combined with some psychosocial aspects of this option may be out of reach for certain patient populations. One can then extrapolate from the Flavin and Coleman study that these patients may be better suited with a fusion if patients with coronal deformities can expect similar results with a fusion to patients receiving a TAR.



**Figure 5:** Varus Ankle Deformity

Another interesting finding is the lack of an expected difference in sagittal range of motion in the two treatment groups. The fusion group post-operatively had  $15.0 \pm 2.2$  degrees and the TAR group had  $19.2 \pm 6.0$  degrees at  $P=.060$ . With a successful tibiotalar fusion there should be no motion remaining at the tibiotalar joint. This “sagittal tibiotalar” range of motion in the fusion group must be coming from other peri-tibiotalar and midtarsal joints including the talonavicular joint, subtalar joint and calcaneal cuboid joints. This extra compensatory motion has been attributed to the increased risk of developing OA in surrounding joints following tibiotalar joint arthrodesis. Further proof of the compensatory efforts of these joints is made by a long-term study by Coester, Saltzman and colleagues. They had long term follow up with ankle fusion patients on average of 22 years and found that 91% of subtalar joints, 57% of talonavicular joints, and 24% of calcaneal cuboid joints had consistently more severe OA compared to the joints on the contralateral side (16). In comparing these two studies the ankle fusion patient may have similar short term results to a patient receiving a TAR in the short term. However,

in the long term the patient with a fusion is at a much higher risk for functional limiting pain and premature deterioration of the talonavicular and subtalar joints. In comparison to the above study Mann, Mann, and Horton looked at the STAR mobile bearing 3 part implant in 80 patients with 91% follow up at 9.1 years. They found that 20% of subtalar joint, 13% of talonavicular joint and 4 % of calcaneal cuboid joint deteriorated a single grade of arthrosis (17). At 9.1 years the risk of DJD to adjacent joints is much lower with a TAR compared to a fusion. However, studies examining TAR outcomes with longer follow ups are needed.

### Conclusion

The best treatment for end stage ankle OA has historically been a successful solid tibiotalar fusion (17). The first generation TARs were met with due criticism related to poor treatment outcomes (18). The advent of the 2nd generation implants, along with initial promising results, have made the TAR a reasonable treatment option in the appropriate patient. As surgeons who consult and advise our patients on treatment options, we must be able to accurately predict the short and long term consequences of our surgical treatments. Current research has shown that treating end stage ankle OA by fusion or arthroplasty may show initial similar results and any differences may actually be insignificant to the patient. However, the long term effects on adjacent joints to the ankle after fusion have been documented (17). This poses the young patient with end stage arthritis the question of whether they want to deal with the potential of a failing implant (which can be revised), or the potential of functionally impairing OA in the subtalar, talonavicular, and calcaneal cuboid joints.

Research has shown us that initial results are promising with improvement seen in both treatment options in walking speed, cadence, step length, sagittal and coronal range of motion, and functional outcomes (12-16). In the end, when choosing which patient is appropriate for which option, many factors need to be taken into consideration. Patient's age, physical demands, co-morbidities, BMI, bony alignment of the forefoot and rear foot, and availability of quality bone stock must all be considered (18). More research is needed to evaluate

the long term effects of TAR on the ankle complex as well as the functional, radiographic and temporospatial methods of evaluating efficacy of the implant. For the time being, current evidence based medicine combined with the patient's clinical, radiographic, and medical presentation must guide treatment.

### References

1. Valderrabano, V; Nigg, BM; von Tschanner, V; et al. Gait analysis in ankle osteoarthritis and total ankle replacement. *Clin Biomech. Bristol, Avon*, 22(8):894-904, 2007
2. Cheng, YM; Chang, JK; Hsu, CY; et al. Lower Tibial Osteotomy for osteoarthritis of the ankle. *Gaoxiong Yi Xue Ke Xue Za Zhi* 10(8):430-7, 1994.
3. Haddad, SL; Coetzee, JC; Estok, R; et al. Intermediate and Long Term Outcomes of Total Ankle Arthroplasty and ankle arthrodesis. A systematic review of the literature. *J Bone Joint Surgery Am*, 89(9):1899-905, 2007.
4. Saltzman, CL; Mann, RA; Ahrens, JE et al. Prospective Controlled Trial of STAR total ankle replacement system versus ankle fusion: initial results. *Foot Ankle International*. 30(7): 579-96. 2009
5. Cushnaghan J, Dieppe P: Study of 500 patients with limp joint osteoarthritis. Analysis by age, sex, and distribution of symptomatic joint sites. *Ann Rheum Dis* 50:8-13, 1991
6. Saltzman CL, Salamon ML, Blanchard GM, et al. Epidemiology of ankle arthritis, report of a consecutive series of 639 patients from a tertiary orthopedic center. *Iowa Orthop J* 25:44-46, 2005
7. Agel J. Coetzee JC, Sangeorzan BJ, Roberts MM, Hansen ST Jr: Functional Limitation of patients with end stage ankle arthritis, *Foot Ankle Int* 26: 537-539, 2005.
8. Ihn JC. Kim SJ, Park IH: In vitro study of contact area and pressure distribution in the human knee after partial and total meniscectomy *Int Orthop* 17:214-218, 1993
9. Brown TD. Shaw DT. In vitro contact stress distributions in the natural human hip. *J Biomech* 16:373-384, 1983.
10. Ateshian GA. Soslowsky LJ, Mow VC. Quantitation of articular surface topography and cartilage thickness in knee joints using stereophotogrametry, *J Biomech* 24:761-776, 1991

11. Kempson GE: Age-related changes in the tensile properties of human articular cartilage: a comparative study between the femoral head of the hip joint and the talus in the ankle joint. *Biochim Biophys Acta* 1075:223-230, 1991.
12. Horisberger M, Hintermann B, Valderrabano V: Alterations of planter pressure distribution in posttraumatic end stage ankle osteoarthritis. *Clin Biomech (Bristol, Avon)* 24:303-307, 2009
13. Nuesch C, Valderrabano V, Huber C, et al. Gait patterns of asymmetric ankle osteoarthritis patients. *Clinical Biomechanics* 27:613-618, 2012.
14. Flavin R, Coleman S, Tenenbaum S, Brodsky J. Comparison of Gait After Total Ankle Arthroplasty and Ankle Arthrodesis. *Foot Ankle Intl* 34(10) 1340-1348
15. Queen R, Biasio B, Butler R et al. Changes in Pain, Function, and Gait Mechanics Two Years Following Total Ankle Arthroplasty Performed with Two Modern Fixed-Bearing Prostheses. *Foot Ankle Intl.* 33-535-542, 2012
16. Coester L, Saltzman C, Leupold J, et al. Long Term Results Following Ankle Arthrodesis for Post-Traumatic Arthritis. *Journal of Bone and Joint Surgery.* 83-A: 219-228, 2001
17. Mann J, Mann R, Horton M. STAR Ankle: Long-Term Results. *Foot Ankle Intl.* 32:473-484.
18. Coughlin M, Saltzman C, Anderson R. Mann's Surgery of the Foot and Ankle. 9th Edition. Saunders. 2014
19. Saltzman CL, Salamon ML, Blanchard GM et al. Epidemiology of ankle arthritis: report of a consecutive series of 639 patients from a tertiary orthopedic center. *Iowa Orthop J* 2005;25:44-6.
20. Brown TD, Johnston RC, Saltzman CL, et al. Posttraumatic osteoarthritis: a first estimate of incidence, prevalence, and burden of disease. *J Ortho Trauma* 2006;20(10): 739-44.
21. Valderrabano V, Horisberger M, Russel I, et al. Etiology of ankle osteoarthritis. *Clin Orthop Relat Res* 2009;467(7):1800-6
22. Ramsey PL, Hamilton W. Changes in Tibiotalar Area of Contact Caused by Lateral Talar Shift. *Journal of Bone and Joint Surgery.* 1976;58-A,3.
23. Lloyd J, Elsayed S, Hariharan K, Tanaka H. Revisiting the Concept of Talar Shift in Ankle Fracture. *Foot and Ankle International.* 2006. Oct;27(10):793-6
24. Zindrick, MR. Hopkins GE. Knight GW. Hopkins CL. Patwardhan AG. Bunch WH. The effect of lateral talar shift upon the biomechanics of the ankle joint. *Orthop Trans.* 9:332-333, 1985.
25. Epstein DM, Black BS, Sherman SL. Anterior Ankle Arthroscopy: Indications, Pitfalls, and Complications. *Foot Ankle Clinics North America.* 20(2015) 41-57.
26. Lui TH. Arthroscopy and endoscopy of the foot and ankle: indications for new techniques. *Arthroscopy* 2007;23:889-902
27. Horisberger M, Valderrabano V, Hintermann B. Posttraumatic ankle osteoarthritis after ankle related fractures. *J Orthop Trauma* 2009;23(1):60-7
28. Pereira DS, Koval KJ, Resnick RB, Sheskier SC, Kummer F, Zuckerman JD. Tibiotalar contact area and pressure distribution: The effect of Mortise Widening and Syndesmosis Fixation. *Foot and Ankle International.* 1996-Vol17(5)

**Image References:**

Figure 1:

[http://www.londonfootandanklecentre.co.uk/images/anatomy/ankle\\_osteoarthritis.jpg](http://www.londonfootandanklecentre.co.uk/images/anatomy/ankle_osteoarthritis.jpg)

Figure 2:

<http://www.star-ankle.com/wp-content/uploads/2011/03/VH-PostOp-Lateral.jpg>

Figure 3:

[http://www.bedleconsulting.com/wp-content/uploads/2014/03/anklefusion\\_1.jpg](http://www.bedleconsulting.com/wp-content/uploads/2014/03/anklefusion_1.jpg)

Figure 4:

<http://www.ohiofac.com/wp-content/themes/medicate-child/images/xray-ankle-replacement.jpg>

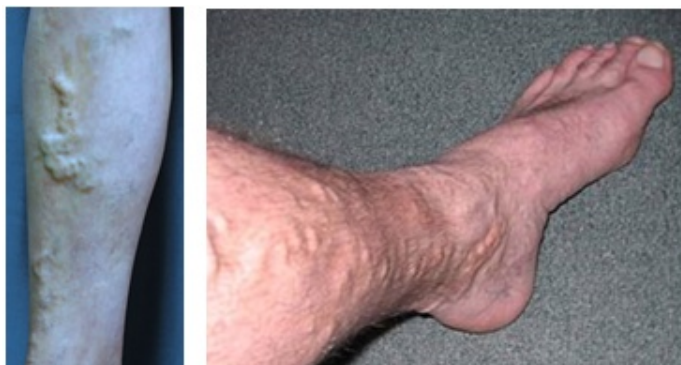Figure 5:

<http://www.bjj.boneandjoint.org.uk/content/88-B/7/909/F4/graphic-8.large.jpg>

# Non-Conventional Treatments for Varicose Veins

Katherine Chao, Pharm.D. · Western University of Health Sciences, College of Pharmacy

Varicose veins are dilated, elongated, tortuous subcutaneous veins. They are  $\geq 3$  mm in diameter when measured in the upright position (1,2). These most commonly occur in the legs and ankles (3). In the United States, an estimated 23% of adults have varicose veins (1). Although varicose veins have long been considered a cosmetic problem, they also frequently cause discomfort, pain, disability, and deterioration in quality of life.



**Figure 1, 2:** Examples of Varicose Veins (19, 20)

The common treatments for varicose veins include compression therapy, open venous surgery, phlebectomy, and medical treatment (1). This article summarizes the non-conventional medical treatment for varicose veins. The most promising medications are horse chestnut seed extract (aescin), flavonoids, centella asiatica, ruscus aculeatus (Butcher's Broom), and calcium dobesilate (1,5,6,7).

## 1. Horse chestnut seed extract (HCSE) – Aescin / Aesculus Hippocastanum

The active component of the extract is the triterpenic saponin, aescin. HCSE exhibits venotonic, vascular protective, anti-inflammatory, and free radical scavenging properties, and appears to reduce abnormally increased capillary permeability and associated edema (7).

A recently updated systemic review discussed the efficacy and safety of horse chestnut seed extract. The author included 17 randomized controlled trials which showed significant improvements in the symptoms of leg pain, edema, pruritus, leg volume, and circumference compared to either placebo or baseline. In the systematic review, fourteen studies reported adverse events. Four studies reported that there were no treatment-related adverse events in the HCSE group. Gastrointestinal complaints, dizziness, nausea, headache, and pruritus were reported as adverse events in six studies. The frequency ranged from 1 to 36% of treated patients. Four other studies reported good tolerability with HCSE (10).

## 2. Flavonoids – Micronized purified flavonoid fraction (MPFF), Diosmin, Hesperidin, Rutosides, and OPCs

Diosmin is synthesized from hesperidin, which is extracted from a type of small immature orange (11). MPFF consists of 90% diosmin and 10% flavonoids. Taking MPFF 1000mg daily for 2 months has been shown to reduce venous distension and venous capacitance and improve venous tone in women with various grades of venous insufficiency. MPFF also carries anti-inflammatory effects and reduces edema (11).

Long-term efficacy of MPFF on CVI patients has been shown in the RELIEF study (12). After 6-month treatment of twice daily doses of 500mg MPFF, the clinical scores of all symptoms have significantly decreased in groups with or without venous reflux. This improvement was also associated with a significant and

continuous progression in the quality of life scores of all patients (12). MPFF appears to be extremely safe and has no substantial side effects in rats and humans (11).

Hydroxyethylrutosides have been reported to relieve leg symptoms associated with varicose veins and to accelerate healing of varicose ulcers. The effect of hydroxyethylrutosides on blood oxygen levels was studied in 1971 and showed Paroven 250mg four times daily for four weeks significantly increased the oxygen levels in blood from varicose veins and improved leg symptoms (18). A systematic review in 2014 found a modest favorable effect of Hydroxyethylrutosides on heavy legs, pain, and cramps. However, it suggested that more evidence was required to support the routine use in practice (21).

A meta-analysis compared the reduction of venous ankle edema in randomized controlled trials between MPFF, hydroxyethylrutoside, ruscus extracts, and diosmin. As shown in table 1, all the venoactive treatments were significantly superior to the placebo in reducing malleolar circumference. MPFF was significantly superior to ruscus extract and hydroxyethylrutoside. Hydroxyethylrutoside and ruscus extracts possess comparable efficacy. The author also revealed the significant superiority of MPFF, ruscus extracts and hydroxyethylrutoside over diosmin (14).

	Mean reduction in ankle circumference (m±SD)	Confidence interval	Population size
MPFF	-0.80±0.53 cm	(-0.85; -0.75)	463
Ruscus extracts	-0.58±0.47 cm	(-0.65; -0.51)	115
Hydroxyethylrutoside	-0.58±0.31 cm	(-0.64; -0.52)	90
Single diosmin	-0.20±0.50 cm	(-0.35; -0.05)	45
Placebo	-0.11±0.42 cm	(-0.16; 0.06)	297

MPFF: micronised purified flavonoid fraction.

**Table 1:** Means, standard deviations and 95% confidence intervals of the reduction in ankle circumference under the effect of the different treatments (14).

### 3. Centella Asiatica

Centella asiatica is a tropical medicinal plant with a long history of therapeutic use. Centella has the potential to enhance connective tissue integrity, elevate antioxidant levels in wound healing, and improve capillary permeability. An important active constituent of centella asiatica, asiaticoside, was isolated and purified in 1940 and the first systematic clinical studies were carried out in 1945. Most clinical studies of centella asiatica used either undefined alcohol or aqueous extracts or one of the following extracts: TECA (titrated extract of centella asiatica), TTFCA (total triterpenoid fraction of centella asiatica), or TTF (total triterpenic fraction) (7).

Mucopolysaccharide is one of the main components of the amorphous cellular matrix (ground substance) that maintains vascular integrity. The biochemical action of centella extract was to reduce serum levels of lysosomal enzymes involved in the degradation of mucopolysaccharides. One study proved the positive effect of the TTFCA extract 30mg three times daily on the pathogenesis of varicose veins and indirectly confirmed the regulatory effects of the extract of centella asiatica on metabolism in the connective tissue of the vascular wall (9). One double-blinded, placebo-controlled study proved the dose-dependent reduction in capillary filtration rate of centella asiatica (TTFCA) extract. The reduced capillary filtration rate was associated with improvement in microcirculation and clinical symptoms (7). In addition, local application of TTFCA extract has been shown to improve vascular tone. In a double-blinded study involving 80 patients, centella extract was applied locally three times daily to patients with various venous disorders. Patients, physicians, and ultrasonic examination noted subjective and objective improvements in symptoms (7).

In 1987, Pointel reported that TECA 60mg or 120mg daily for 2 months significantly improved the symptoms of heaviness in the lower limbs, edema, ambulatory lower limb pain, and overall evaluation by the patient (8).

#### 4. *Ruscus Aculeatus* (Butcher's Broom)

Extract of *ruscus aculeatus* is effective in increasing venous tone because of its anti-inflammatory and astringent properties. The active biochemical constituent is the saponin glycoside ruscogenin (7). The main indication of the butcher's broom rhizome preparation (*ruscus extract*) is the therapy of complaints from chronic venous insufficiency such as itching, tired, heavy legs, sensation of tension, and pain. Pharmacological studies showed *ruscus* extracts increase venous tone, improve capillary wall sealing, and have antiphlogistic and diuretic effects (13).

In a multicenter, double-blinded, randomized, placebo-controlled trial with women suffering from chronic venous insufficiency (CVI), the efficacy and safety of butcher's broom rhizome extract (*ruscus aculeatus*, fagorutin *ruscus kapselm*) was studied. Oral *ruscus* extract (72-75mg per day) significantly improved lower leg volume changes, ankle circumference, lower leg circumference, and subjective symptoms (heavy tired legs, and sensation of tension), but not the quality of life. The tolerability was judged as very good by 76.8% of the subjects and as good by 23.2% of the subjects with *ruscus* extract treatment (13).

Furthermore, the meta-analysis from Allaert FA, which compared the reduction of venous ankle edema in randomized controlled trials of MPFF, hydroxyethylrutoside, *ruscus* extracts, and diosmin suggested that the mean reduction in ankle circumference was 0.58cm with *ruscus* extracts, which is comparable to the efficacy of hydroxyethylrutoside (14).

#### 5. Calcium Dobesilate

Calcium dobesilate (2,5 dihydroxy-benzenesulfonate) is a synthetic drug to treat chronic venous disease. It acts on the endothelium of capillaries by blocking the hyperpermeability, inhibiting platelet aggregation, and increasing red cell flexibility. These mechanisms contribute to an edema-protective effect (15).

A meta-analysis study showed that calcium dobesilate significantly improved night cramps and discomfort, with higher efficacy in more severe disease. The author concluded that 1000 mg/day is as effective and safe as 1,500 mg/day. Frequency of adverse events was not significantly different from placebo (15).

Another study in 2008 stated that there was no significant improvement in overall quality of life or symptoms of CVD after 3 months treatment of 500mg oral calcium dobesilate twice daily, but there was a significant improvement at the end of 12 months (16). There were a few limitations in the study which might favor the placebo group and reduce the chance to find a difference. The study used a secondary endpoint that was not as precise as the endpoint used in other studies. In addition, 26% loss of follow-up might affect the result as well.

Another randomized controlled trial in 2011 concluded that calcium dobesilate is more effective in improving symptoms of CVD compared to placebo, but not the quality of life. The observed adverse events correspond to the known profile. The most common related adverse events are gastrointestinal disorders (17).

In summary, horse chestnut seed extract (aescin), flavonoids, *centella asiatica*, *ruscus aculeatus* (Butcher's Broom), and calcium dobesilate are shown to reduce the symptoms of varicose veins and improve quality of life with minimum adverse effects. Although more evidence is required to support the routine use of non-conventional treatments for varicose veins, this is a promising area for future studies.

#### Reference:

1. Gloviczki P et al. The care of patients with varicose veins and associated chronic venous diseases: Clinical practice guidelines of the Society for Vascular Surgery and the American Venous Forum. *Journal of vascular surgery* 2011; 53: 1S – 48S.
2. Up to date. Overview and management of lower extremity chronic venous disease. Up to date. June 26, 2013.
3. WebMD. Varicose Veins - Topic Overview. Aug 17, 2012.
4. DynaMed. Varicose Veins. Aug 23, 2013.



5. Martinez MJ, Bonfill X, Moreno RM, Vargas E, Capella D. Phlebotonics for venous insufficiency. *Cochrane Database Syst Rev* 2005: CD003229.
6. PCCA. Treatment options for lower limb varicose veins. PCCA. Accessed Aug 29, 2013.
7. MacKay D. Hemorrhoids and varicose veins: a review of treatment options. *Alternative medicine review* 2001; 6: 126-140.
8. Pointel JP, Boccalon H, Cloarec M, et al. Titrated extract of *Centella asiatica* (TECA) in the treatment of venous insufficiency of the lower limbs. *Angiology* 1987; 38: 46-50.
9. Arpaia MR, Ferrone R, Amitrano M, et al. Effects of *Centella asiatica* extract on mucopolysaccharide metabolism in subjects with varicose veins. *Int J Clin Pharmacol Res.* 1990; 4: 229-233.
10. Pittler MH, Ernst E. Horse chestnut seed extract for chronic venous insufficiency. *Cochrane Database of Systematic Reviews* 2012, Issue 11. Art. No.: CD003230. DOI: 1002/14651858.CD003230.pub4.
11. Katsenis K. Micronized Purified Flavonoid Fraction (MPFF): A Review of its Pharmacological Effects, Therapeutic Efficacy and Benefits in the Management of Chronic Venous Insufficiency. *Current Vascular Pharmacology* 2005; 3: 1-9.
12. Jantet G. Chronic venous insufficiency: worldwide results of the RELIEF study. Reflux assessment and quality of life improvement with micronized flavonoids. *Angiology.* 2002; 53: 245-256.
13. Vanscheidt W, Jost V, Wolna P, et al. Efficacy and Safety of a Butcher's Broom Preparation Compared to Placebo in Patients Suffering from Chronic Venous Insufficiency. *Arzneimittelforschung.* 2002; 52 (4): 243-250.
14. Allaert F. Meta-analysis of the impact of the principal venoactive drugs agents on malleolar venous edema. *International Angiology.* 2012; 31 (4): 310-315.
15. Ciapponi A, Laffaire E, Roque M. Calcium dobesilate for chronic venous insufficiency: a systematic review. *Angiology.* 2004; 55(2): 147-154.
16. Martinez-Zapata MJ, Moreno RM, Gich I, et al. A Randomized, double-blind multicenter clinical trial, comparing the efficacy of calcium dobesilate with placebo in the treatment of chronic venous disease. *European Society for Vascular Surgery.* 2008; 35: 358-365.
17. Rabe E, Jaeger KA, Bulitta M, Pannier F. Calcium dobesilate in patients suffering from chronic venous insufficiency: a double-blind, placebo-controlled, clinical trial. *Phlebology.* 2011; 26 (4): 162-168.
18. Mcewan A, Mcardle C. Effect of Hydroxyethylrutosides on Blood Oxygen Levels and Venous Insufficiency Symptoms in Varicose Veins. *British Medical Journal.* 1971; 2: 138-141.
19. John J. B., Greet W.S. etc. Chronic Venous Disease. *The New England Journal of Medicine.* 2006; 335: 488-98.
20. Wikipedia. Varicose veins. *Wikipedia.com.* 7 Mar. 2015. Web. 12 Mar. 2015.
21. Z. Aziz, W. L. Tang, N.J. Cong, and L.Y. Tho. A systematic review of the efficacy and tolerability of hydroxyethylrutosides for improvement of the signs and symptoms of chronic venous insufficiency. *Journal of Clinical Pharmacy and Therapeutics.* 2015; 40: 177-185.

# The Phantom Limb – History and Reflection

Kevin Ragothaman, MS3 · *Western University of Health Sciences, College of Podiatric Medicine*

## Introduction

Limb amputation is a global issue. In the US alone 1.6 million people were living with the loss of a limb in 2005, a number that is expected to double by the year 2050 (1). The most common etiologies of amputation include vascular disease, trauma, and cancer. Between 1988 and 1996, most dysvascular amputations involved the lower limb. In fact, dysvascular disease is a major contributor of amputations for adults aged 65 and older, an important finding as the elderly population continues to increase (2).

Many who undergo amputation in the operating room possess a limb that is unsalvageable due to disease. The pangs of pain that emanate from a limb mired by infection and gangrene is oftentimes enough to prompt patients to undergo amputation. However, the pain may remain to haunt the patient upon removal of the limb. Additionally, the pain that occurs post-operatively following an amputation of a body part may be present for a variety of reasons, including phantom limb pain, residual limb pain, stump neuromas, pain from the prosthesis, or a painful scar (3).

Medical advancements have allowed us to delineate the aforementioned causes of post-amputation pain and care for patients based on the etiology of the symptoms. However, the phantom limb is a post-amputation phenomenon that has perplexed physicians for ages. Phantom sensations refer to the feeling that the limb is still present, while phantom limb pain involves painful sensations in the lost limb. Both of these were first described in traumatic amputations of soldiers (4). The common sensation and pain complaints associated with the phantom limb may involve a single quality or a combination, including warmth, cold, itching, cramping, burning, throbbing, piercing, tearing, and stinging, which can either occur continuously throughout the day or at

random intervals (5). Such sensations can occur at any point after surgery, either immediately after anesthesia wears off or many years following amputation, and can be elicited by a variety of mechanisms, including emotional factors or environmental triggers. Spontaneous onset has also been noted as a potential trigger, as many individuals do not remember a specific inciting factor (6).

What complicates matters is the fact that phantom limb pain and various etiologies of stump pain can co-exist (7). This poses difficulties for those attempting to conduct large trials of amputees experiencing phantom limb pain and sensations. Some authors suggest that anyone who undergoes an amputation will likely experience phantom limb pain (3). What is clear, however, is the negative impact that phantom limb pain poses on both mental and physical quality of life (8). As the number of amputees continue to increase, it is important for us to continue to attempt to elucidate the basis for which this phantom limb phenomenon exists.

A manuscript by Anderson-Barnes et al. entertains the idea of proprioceptive memory contributing to the sensations felt with the phantom limb in traumatic amputees. The authors describe instances of soldiers from the Walter Reed Army Medical Center in Washington, DC feeling their phantom limb stuck in the position in which it was held prior to their amputation, examples of which include a cramped phantom arm with hand pulling the trigger of a rifle or the feeling of a phantom leg constantly pushing against a wall (9). From these accounts, a feasible explanation could be that the phantom limb that is frozen in the intact limb's position is unable to obey the motor commands sent from the brain. How, then, could a diabetic amputee's post amputation experience differ from that of a traumatic amputee? Some have supposed that diabetic amputees experience less phantom limb pain than traumatic

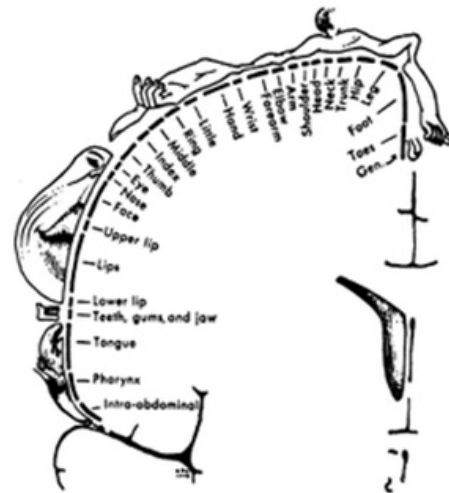
amputees, possibly due to the co-existence of neuropathy in many of these patients (10). However, a retrospective analysis of 97 limbs conducted in the UK revealed no significant difference in prevalence of phantom limb pain or phantom sensations in diabetic lower-limb amputees compared to those without diabetes. They also found no significant difference in intensity of phantom limb pain experienced (11).

### Neurological basis of the Phantom Limb

What insight does the presence of the phantom limb give into the mechanics of the brain and its interaction with the rest of the body? How is it that, even upon forcefully wrenching away an extremity, the brain neglects to forget the strong connection it once had with the limb?

Ramachandra, a neurologist from UCSD, engaged in important work concerning the brain and its dynamic role in constructing its perception of the body image after removal of a limb. The idea that the brain is altered upon nerve deafferentation from limb amputation was introduced by Timothy Pons, who used macaque monkeys whose sensory nerves from one arm were severed in a previous experiment conducted by another group. Such intrusion of the macaques' bodies was considered absurdly lewd in modern standards of animal rights, and the macaques were to be put down. Pons seized upon the opportunity to conduct an experiment that would change neuroscience. Using electrodes placed into the sensory cortex of the macaques' brains, Pons demonstrated invasion of the sensory cortex of the face into that of the arm and hand. When the authors touched the monkey's face, the hand and arm cortex responded (12). This experiment largely suggests the concept of neural plasticity- the idea that the adult brain undergoes dynamic changes- moreso than previously believed. A visual representation of the sensory cortex is demonstrated by the Penfield map (13, Fig. 1). It makes sense that invasion of the arm sensory cortex would be from the adjacent face sensory cortex. Ramachandra demonstrated similar findings in humans in a series of case studies of arm amputees. By stroking patients' faces with a Q-tip, he found that specific points on the lower portion of the

face ipsilateral to amputation site corresponded to specific digits of the lost hand. In one of the cases, the area corresponding to the thumb on the face expanded, supporting the idea that the sensory cortex continued to change with prolonged time from amputation date (14). Given the proximity of the foot with the genitals on the Penfield map, one may expect to see a similar sensory relationship between the two organs. Indeed, Ramachandra notes one such case in which a patient felt their orgasms were stronger since they felt augmented sensations in the phantom limb (15). Additionally, a survey of two tertiary care hospitals yielded 13 individuals who felt pain or sensations in their phantom lower limb with micturition or emptying their bowels. One individual who underwent a femoral amputation felt phantom pain when his bladder was full and was relieved when his bladder was emptied (16).



**Figure 1.** Penfield 'homunculus' map. A visual representation of the brain's sensory cortex.

In accordance with the theory of proprioceptive memory provided by Anderson-Barnes et al, Ramachandra postulates the occurrence of a "learned paralysis" prior to amputation. Often times, as is the case with diabetic or dysvascular amputees, the infected limb is immobilized for a prolonged period of time. When the brain sends motor signals to the limb, it is met with a visual sign that, in essence, provides an inhibitory signal that the limb cannot move (15). An impression of the conformation of the immobilized limb is thus etched into the brain. Upon removal of the limb by amputation, the brain is conditioned by this "learned paralysis" and continues to think that an immobilized limb is present.

## Mirror Box Therapy

If the patient is met with visual confirmation that the limb is indeed moving when the brain instructs it to do so, would that then relieve the patient from the detrimental effect of the phantom limb? Ramachandra sought to examine this by using the cheapest way to recreate the missing limb – by using a mirror. The reflection of the opposite intact limb could trick the brain into believing the motor impulses are causing movement in a limb that is actually not present. Ramachandra attempted this method on numerous cases and was met with some positive results (15). For example, as soon as one of his patients peered into the mirror while moving his intact limb, he felt as though his phantom limb was moving. Another patient experienced frequent clenching of his phantom hand. When asked to clench and unclench his intact hand while looking into the mirror, the patient felt immediate relief. Further case reports have also shown effective pain relief using mirror therapy for arm amputees for whom medications, nerve blocks, and physical therapy did not work (17). However, no large trials have demonstrated the efficacy of mirror therapy for phantom limb pain. Additionally, side effects such as confusion and dizziness were reported in a single study (18).

Although there is currently no consensus on effective treatment for phantom limb pain, the amount of progress that has been made in illuminating the pathophysiology behind its occurrence is promising. A forecasted increase in number of amputations in the coming decades points to the need to find effective therapy to administer post-operatively to our patients. Hopefully this will be accomplished as more neurological breakthroughs are made and chronic pain conditions continue to be studied.

## References

1. Ziegler-Graham K, MacKenzie EJ, Ephraim PL, Travison TG, Brookmeyer R. Estimating the prevalence of limb loss in the United States: 2005 to 2050. *Arch Phys Med Rehabil.* 2008 Mar;89(3):422-9. doi: 10.1016/j.apmr.2007.11.005.
2. Dillingham TR, Pezzin LE, MacKenzie EJ. Limb amputation and limb deficiency: epidemiology and recent trends in the United States. *South Med J.* 2002

Aug;95(8):875-83.

3. Ephraim PL, Wegener ST, MacKenzie EJ, Dillingham TR, Pezzin LE. Phantom pain, residual limb pain, and back pain in amputees: results of a national survey. *Arch Phys Med Rehabil.* 2005 Oct;86(10):1910-9.
4. Casale R, Alaa L, Mallick M, Ring H. Phantom limb related phenomena and their rehabilitation after lower limb amputation. *Eur J Phys Rehabil Med.* 2009 Dec;45(4):559-66. Epub 2009 Feb 26.
5. Hill A. Phantom limb pain: review of the literature on attributes and potential mechanisms. *J Pain Sympt Manag* 1999;2:125-42
6. Giummarra MJ, Georgiou-Karistianis N, Nicholls ME, Gibson SJ, Chou M, Bradshaw JL. The menacing phantom: what pulls the trigger? *Eur J Pain.* 2011 Aug;15(7):691.e1-8. doi: 10.1016/j.ejpain.2011.01.005. Epub 2011 Feb 11.
7. Hsu E, Cohen SP. Postamputation pain: epidemiology, mechanisms, and treatment. *J Pain Res.* 2013;6:121-36. doi: 10.2147/JPR.S32299. Epub 2013 Feb 13.
8. Sinha R, van den Heuvel WJ, Arokiasamy P. Factors affecting quality of life in lower limb amputees. *Prosthet Orthot Int.* 2011 Mar;35(1):90-6. doi: 10.1177/0309364610397087.
9. Anderson-Barnes VC, McAuliffe C, Swanberg KM, Tsao JW. Phantom limb pain--a phenomenon of proprioceptive memory? *Med Hypotheses.* 2009 Oct;73(4):555-8. doi: 10.1016/j.mehy.2009.05.038. Epub 2009 Jun 24.
10. Bloomquist T. Amputation and phantom limb pain: a pain-prevention model. *AANA J.* 2001 Jun;69(3):211-7.
11. Clark RL, Bowling FL, Jepson F, Rajbhandari S. Phantom limb pain after amputation in diabetic patients does not differ from that after amputation in nondiabetic patients. *Pain.* 2013 May;154(5):729-32. doi: 10.1016/j.pain.2013.01.009. Epub 2013 Jan 26.
12. Pons T, Garraghty PE, Ommaya AK et al. *Science* 252, 1857–1860 1991
13. Schott GD. Penfield's homunculus: a note on cerebral cartography. *J Neurol Neurosurg Psychiatry.* 1993 Apr;56(4):329-33.
14. Ramachandran VS, Stewart M, Rogers-Ramachandran DC. Perceptual correlates of massive cortical reorganization. *Neuroreport* 1992; 3: 583-6
15. Ramachandran VS, Hirstein W. The perception of phantom limbs. The D. O. Hebb lecture. *Brain.* 1998 Sep;121 ( Pt 9):1603-30.

16. Sivan M, Stoppard E, Kirker S. Alteration in phantom pain and sensation with visceral movement. *PM R*. 2010 Jun;2(6):576-8. doi: 10.1016/j.pmrj.2010.02.005.
17. Kim SY, Kim YY. Mirror therapy for phantom limb pain. *Korean J Pain*. 2012 Oct;25(4):272-4. doi: 10.3344/kjp.2012.25.4.272. Epub 2012 Oct 4.
18. Casale R, Damiani C, Rosati V. Mirror therapy in the rehabilitation of lower-limb amputation: are there any contraindications? *Am J Phys Med Rehabil*. 2009 Oct;88(10):837-42. doi: 10.1097/PHM.0b013e3181b74698.

# Plantar Warts, Folklore, and the Placebo Effect- A Review

Colin McKay, MS2 · *Western University of Health Sciences, College of Podiatric Medicine*

---

## Introduction

History is riddled with folklore, especially when it comes to the causes and treatments of warts. Folklore and medicine have often walked hand in hand in many cultures all over the world. Folklore may have had a proper place where medical treatments were not available, due to the placebo effect, however, it is our job as medical professionals to pursue evidence based medicine.

Plantar warts, also known as verruca, myrmecia and verruca plantaris (6), are caused by the human papilloma virus (HPV). HPV is a DNA virus, and primarily infects human keratinocytes of the skin or mucous membranes. HPV is very common, but most carriers are asymptomatic. HPV types 2, 27 and 57 were most frequently observed with warts, while HPV 1, 2, 63 and 27 were commonly observed on clinically normal skin. (9) Seventy percent of clinical HPV infections, in young men and women, may regress to subclinical in one year and ninety percent in two years. (8)

Even though there are many subtypes, warts today are classified more by where they are present on the body. Warts found on the genitals are genital warts, and warts found on the plantar foot are plantar warts. Furthermore, the classification of verruca vulgaris is designated for warts with a hyperkeratotic appearance, and verruca planae are warts with a smoother appearance. (7)

Warts are usually benign, but can cause pain, especially when located on the plantar foot. They can be aesthetically displeasing. There are certain risks of cancer for genital warts, and when HPV particles are inhaled it can lead to laryngeal papillomatosis, which is a life-threatening condition. (7) Warts can also turn into Verrucous carcinoma of the foot, which is often misdiagnosed as plantar warts. (12)

Plantar warts ICD-9 code accounted for 10.2% of patient visits for warts even though they only make up 0.5% of all warts reported. (1) Older populations have higher trends of getting warts, but race and gender seem to be unrelated. (1)

Spontaneous remission of warts occurs in up to two-thirds of patients within two years (19). Warts in people with healthy immune systems are the most likely to regress without therapy (9,20). This may be part of the reason why warts seem to have more well known folklore, because if a wart is “cured” or spontaneously resolves during a superstitious treatment, folklore is born and thrives

## History

The term ‘verruca’ was first used by Sennertus, a German physician in the 1500’s. Originally, the word meant a steep place or height. Sennertus applied the term to warts because ‘they appear on the surface of the skin like the eminences of little hills’. (3) It wasn’t till 1907 that it was proposed that warts had a viral origin, by Ciffo, who successfully inoculated warts from infected children to adults, and later successfully inoculated himself by the same experiment. (3) Then in 1969 Melnick classified the wart virus in the papova virus group. (3)

In the 1960’s the peak age of incidence was 5-19 years of age, affecting more females than males. (10)

The most common medical modality used half a century ago was diathermy (burning of subcutaneous tissue) plus general anesthetic, which had a reported 92.9 % cure rate (10).

## Folklore

One cannot go very far back into history without finding various accounts of folklore on the subject of warts. The not-so ancient history is a rich spring of conjectures of the causes of warts and its cure. There were many

myths of how one obtained warts, and how one got cured of warts.

### Causes According to Folklore

There are various ways people have believed you could obtain warts. Some myths of how one obtained warts was wetting hands in water where eggs have been boiled, solitary habits (sexual promiscuity), and foam of the sea shore. (3)

### Cures by Transference

Superstitious cures can be divided into cures by transferring the warts to another person or object, or other cures. The following are beliefs of how one could transfer his warts to another person or object:

- Rubbing warts against a man who has an illegitimate child without his knowing. (3)
- If you stick a pin through a wart, and put it in the street, the finder of the pin will get the wart. (17)
- There are other folklore of transferring warts to other objects or plants or animals.
- In Sweden, the people would catch a long-horned grasshopper, with the belief that the insect would bite off their warts. Subsequently it was named “wart-biter” in Swedish. (3)

### Other cures

The following are other beliefs of how people could cure warts:

- Stealing meat, rubbing it on the wart, and throwing it where a dog would find it and eat it. (17)
- In Scotland they said to go to a cross road, lift a stone and rub the warts w/ the dust beneath it, repeating the rhyme:  
‘A’m ane, the wart’s twa,  
The firs ane it come by  
Tacks the wart awa’. (3)
- Cut a stick to be the same size as the circumference of the wart and burring it. Once it decays the wart will vanish. (22)
- In Northeast Poland, an area known as Masuria, a pea is taken for each wart. The peas are then thrown "gently" into the bake oven just after the bread has been removed. One must run out of the house quickly before the popping sound of the peas can be heard.(21)
- In Donegal it is suggested you throw some clay from under your right foot in the path by which a funeral is going and say ‘corpse of clay, carry my warts away’. (3)

### Literature

Even popular literature has portrayed this medical folklore. Mark Twain’s Huckleberry Finn describes this cure:

“You got to go all by yourself, to the middle of the woods, where you know there's a spunk-water stump, and just as it's midnight you back up against the stump and jam your hand in and say:

‘Barley-corn, barley-corn, injun-meal shorts,  
Spunk-water, spunk-water, swaller these warts,’

and then walk away quick, eleven steps, with your eyes shut, and then turn around three times and walk home without speaking to anybody. Because if you speak the charm's busted.” (Huckelberry Finn, chapter 6)

### Today’s folklore

If you define folklore as belief in something due to anecdotal evidence, then today the internet is rife with folklore. Doing a quick search on the internet you can find that everyone has home-remedies that I have not found in any scholarly articles. After a brief search online, I found many home-treatments, which included:

putting a potato on it, soaking it in pineapple juice, putting banana mash on it, to putting honey on it. Putting duct tape is particularly mentioned. Its efficacy will be discussed below.

## Diagnosis

Diagnosis of plantar warts is based on clinical presentation. Plantar wart has the classic appearance of a cauliflower like lesion on the skin with tiny black petechiae in the center, small hemorrhages under the skin. It can occur in both hands and feet. On the feet they are most likely found on soles of the feet and toes. They can look like calluses or corns, but close observation will reveal skin striations.

Diagnosis can be performed by taking a 15 blade to scrape off hyperkeratotic debris and reveal thrombosed capillaries or seeds. A dermatoscopic examination is done to show homogenous black to red globules and dots. (18)

## Treatments

Common treatments of warts deal with Salicylic acid and liquid nitrogen. A 2012 meta-analysis of randomized trials that looked at salicylic acid for wart treatment was better than placebo for remission of warts. (23) However, it may not be as effective as desired. A study that looked at 12 week daily treatment with Salicylic acid showed complete clearance only 10-15% of cases. (24) Liquid nitrogen is painful, and may not be good to use on children for that reason.

The basic therapeutic strategy for treating warts is extirpation of the epidermal stem cells infected by the HPV. (13) The most commonly used treatment today is topical imiquimod (approved by FDA in 1997), but there is not a controlled randomized double blind study for this drug. (1) In another source it was found that cryotherapy using liquid nitrogen is the first-line treatment for inducing necrosis of warts, which has a cure rate that varies from 26-93% (13). Long-pulsed 1064-nm neodymium:yttrium-aluminum-garnet laser has been shown to be effective treatment for refractory warts on hands and feet. (13). Cidofovir is a potent antiviral drug that acts competitively, inhibiting viral DNA polymerase. (14) Cantharidin, a topical vesicant which causes intraepidermal acantholysis. (11)

Other commonly used methods include salicylic acid, cantharidin, and podophyllin. (6) In regards to procedural treatments, removal or physical destruction of the lesion is the primary objective. Procedural options include cryosurgery, surgical excision, electrodesiccation and curettage, and laser therapy. (6)

Other treatments were found highly variable, or not effective, like griseofulvin, and simple trimming of the wart with a razor blade alone. (2, 15) However simple trimming of the wart and applying mole skin can be done to treat the pain.

Duct tape has been believed by many in the community to work. The evidence of the effectiveness of duct tape is conflicting, but there was a meta-analysis of two placebo-controlled randomized trials that did not find a statistically significant difference between the efficacy of placebo and duct tape. (23)

## Prevention

HPV is spread by direct and indirect contact from an infected host. Avoiding direct contact with infected surfaces such as communal changing rooms, shower floors and benches; avoiding sharing of shoes and socks and avoiding contact with warts on other parts of the body and on the bodies of others may help reduce the spread of infection. Infection is less common among adults than children. (16)

It has also been believed by older studies that barefoot dancing or swimming may increase risk of getting warts. (10)

## The Placebo Effect

The type of folklore discussed above pervades multiple cultures all over the world. Although purely anecdotal, and without scientific basis, these methods may have been useful as a treatment due to the placebo



effect. Placebo effects can work via power suggestion. (5) It has been found that the placebo effect is most pronounced and relevant when a treatment's success or failure depends largely on the subjective experiences of patients. (4) This may explain the persuasive nature that medical folklore has on some people. Studies have found that an open label placebo still produced a placebo effect and was about 20% more effective than no treatment.(4) Unproved home remedies based on folklore, or folk-cures may be beneficial to people if they have no other options available.

Researchers have used various technologies to show there are physiological explanations for the placebo effect. They have shown that there are objective changes in biological and chemical systems in the brain and body. (4, 5) There is also an ever expanding list of therapeutic effectiveness of placebos, from Achne and asthma to Lyphosarcoma. (25)

There are two groups of people in the placebo effect. Placebo reactors and nonreactors, those that respond to placebo, and those that don't. These two groups have been studied, and even though education, IQ, gender, did not differentiate these two groups, personality characteristics like friendly, talkative, less hostile, and more seemed to differentiate them. (25). In summary, those that had more confidence in the healthcare system tended to be a reactor, and those that didn't, a nonreactor. (25)

What do we do with this information? As physicians we also can have an effect on outcome of treatment. Direct psychological variables of placebo responses consist of desires, expectations, and emotions that target prospective symptom changes. (5) We can portray to the patient a face of caring and healing. It is important to address patient's doubts and questions. Making the patient feel emotionally safe and setting a caring environment are just as much a part of the job of the physician as administering treatments. Future issues that have been stated by other studies is the need for physicians to be educated about the features and underlying mechanisms of placebo so that they can enhance placebo components of therapy. (5) You cannot write a prescription without the element of placebo (25)

### **Special considerations**

Verrucous carcinoma of the foot is a low grade squamous cell carcinoma that is often misdiagnosed initially as plantar warts. Its metastatic potential is low, but can invade deep into the foot. (12) It predominates in males 40's and 60's

If a patient presents with recurring plantar warts, a biopsy should be considered to rule out carcinoma. (12)

### **Conclusion**

Plantar warts have a long rich history, and are mostly asymptomatic but may be painful and require treatment. The placebo effect may help with treatment of all sorts of diseases including plantar warts. Placebo effect is 20% more effective than no medical treatment at all. Physicians should be acquainted with the mechanisms of the placebo effect so as to complement their treatment of the patient. Imiquinod is the most common treatment for plantar warts.

### **Resoures**

- 1). Reeder VJ, Gustafson CJ, Davis SA, Fleischer AB Jr, Huang WW, "The Treatment and Demographics of warts, An analysis of national trends," <http://www-ncbi-nlm-nih-gov.proxy.westernu.edu/pubmed/24301243>
- 2). George T. Manilla, MD, Thomas K. Hood, MD, and Norman R. Eakin, RPh. "Treatment of plantar warts." Elko, Nevada
- 3). D. A. Burns. "Warts and all' – the history and folklore of warts; a review. 1992 Jan; volume 85 of the Journal of the Royal society of medicine, page 37
- 4.) Putting the placebo effect to work. Harvard Health Letter [serial online]. April 2012;37(6):1-2. Available from: Health Source: Nursing/Academic Edition, Ipswich, MA. Accessed February 7, 2015.

- 5). Donald D. Price, Damien G. Finniss, and Fabrizio Benedetti, "A Comprehensive Review of the Placebo Effect: Recent Advances and Current Thought" *Annual Review of Psychology*(2008) Vol. 59: 565-590
- 6). James, William D.; Berger, Timothy G.; et al. (2006). *Andrews' Diseases of the Skin: clinical Dermatology*. Saunders Elsevier. ISBN 0-7216-2921-0.
- 7). Virginia J. Reeder MD, Cheryl J. Gustafson MD, Scott A. Davis MA, Alan B. Fleischer Jr. MD, William W. Huang MD MPH, "The Treatment and Demographics of Warts: An Analysis of National Trends" *J Drugs Dermatol*. 2013;12(12):1411-1415
- 8). Goldstein MA, Goodman A, del Carmen MG, Wilbur DC; Goodman; Del Carmen, MG; Wilbur (March 2009). "Case records of the Massachusetts General Hospital. Case 10-2009. A 23-year-old woman with an abnormal Papanicolaou smear". *N. Engl. J. Med.* 360 (13): 1337–44. doi:10.1056/NEJMcpc0810837. PMID 19321871
- 9). De Koning MN, Quint KD, Bruggink SC, Gussekloo J, Bouwes Bavinck JN, Feltkamp MC, Quint WG, Eekhof JA (2014). "High prevalence of cutaneous warts in elementary school children and ubiquitous presence of wart-associated HPV on clinically normal skin". *The British journal of dermatology*. doi:10.1111/bjd.13216. PMID 24976535
- 10). A. Barr, R.B. Coles. "Plantar warts- a statistical survey". Page 226,
- 11). Torbeck R, Pan M, DeMoll E, Levitt J, "Cantharidin: a comprehensive review of the clinical literature" *Dermatol Online J*. 2014 Jun 15;20(6). pii: 13030/qt45r512w0.
- 12). Verrucous carcinoma of the foot, not your typical plantar wart: A case study, Diandra K. Gordon, Erinn N. Ponder, B. Hudson Berrey, Melanie J. Kubik, Joseph Sindone. Elsevier, volume 24, issue 2, june 2014, pages 94-98
- 13). Utako Kimura, Kaori Takeuchi, Ayako Kinoshita, Kenji Takamori and Yasushi Suga "Long-pulsed 1064-nm neodymium:yttrium–aluminum–garnet laser treatment for refractory warts on hands and feet " *The Journal of Dermatology*. Volume 41, Issue 3, pages 252–257, March 2014
- 14). Padilla España; Laura, del Boz, Javier; Fernández Morano, Teresa; Arenas Villafranca, Javier; de Troya Martín, "Magdalena; Topical cidofovir for plantar warts" *Dermatologic Therapy*. 2014 27.2
- 15). Aditya K. Gupta MD PhD FRCP(C), Elizabeth A. Cooper HBSc BSc, Jenna E. Bowen MS "Meta-analysis: Griseofulvin Efficacy in the Treatment of Tinea Capitis". *Journal of Drugs in Dermatology* 7.4 (2008) 369
- 16). "Understanding Plantar Warts". Health Plan of New York. Retrieved 2007-12-07
- 17). Wayland Debs Hand. "Magical Medicine; The folkloric component of medicine in the Folk Belief, custom, and Ritual of the peoples of Europe and America
- 18) Bae JM, Kang H, Kim HO, Park YM, Differential diagnosis of plantar wart from corn, callus and healed wart with the aid of dermoscopy. *Br J Dermatol*. 2009 Jan;160(1):220-2.
- 19). Pyrhönen S, Johansson E. Regression of warts. An immunological study. *Lancet* 1975; 1:592.
- 20). Rogozinski TT, Jablonska S, Jarzabek-Chorzelska M. Role of cell-mediated immunity in spontaneous regression of plane warts. *Int J Dermatol* 1988; 27:322.
- 21). Milton Ross, Warts in Medical Folklore of Europe, *Int J Dermatol*. 1979 Jul-Aug;18(6):505-9.
- 22). Wayland D. Hand, Measuring and plugging: the Magical containment and transfer of disease, *Bull Hist Med*. 1974 ,Summer;48(2):221-33.
- 23). Kw, ok CS, Gibbs S, Bennett C, Holland R, Abbott R, Topical Treatments for cutaneous warts. *Cochrane Database syst Rev*, 2012;9 CD001781
- 24). Cockayne S, Curran M, Denby G, Hashmi F, Hewitt C, Hicks K, Jayakody S, Kang'ombe A, McIntosh C, McLarnon N, Stamuli E, Thomas K, Turner G, Torgerson D, Watt I (2011). "EVERT: Cryotherapy versus salicylic acid for the treatment of verrucae--a randomised controlled trial". *Health technology assessment (Winchester, England)* 15 (32): 1–170. doi:10.3310/hta15320. PMID 21899812.
- 25). Granville G. de Oliveria, The Placebo effect, a brief review, *Am J Ther*. 1995 Mar;2(3):217-224.

# Case Study: Adult Acquired Talipes Equinovarus Deformity Secondary to Neuromuscular Disorder

Jared Leber, MS3 · Western University of Health Sciences, College of Podiatric Medicine

## Background

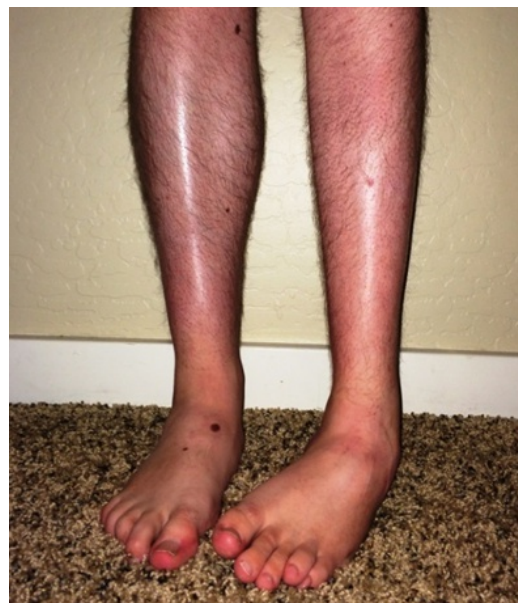Z.L. is a 22 year-old Caucasian male with a chief complaint of painful, unsteady gait secondary to a left deformed foot. The patient was born with a seizure disorder. The seizure foci were determined to originate in multiple locations in the right cerebral hemisphere as identified by PET scan. Treatment was a complete right hemispherectomy. As a side effect of the procedure, the patient suffered from a progressive neuromuscular talipes equinovarus. The patient's lower extremity was treated with weekly physical therapy sessions from ages 1 to 15. The leg was supported by a solid ankle foot orthotic (AFO) since age one. Z.L. reported difficulty ambulating and discomfort when walking more than 500 feet. Z.L. also experienced recurrent ingrown toenails and painful calluses on the lateral aspect of the left foot. The patient denies other significant medical conditions and has no complaints concerning the right foot or leg.

Z.L. continues to be followed by a neurologist for his seizure disorder. For the past 14 years the patient's left foot has not been treated with formal physical therapy. In his early years, the patient was seen by a physical therapist weekly for range of motion and strengthening exercises. In more recent years, he has been treated two times daily with passive and active range of motion exercises by his parents at home and continues to wear his AFO with a standard athletic shoe. Z.L. has shown no improvement since the start of treatment, and his gait continues to worsen.

The purpose of this study is to better understand current recommended treatment modalities in equinovarus foot deformities that result from a progressive neuromuscular talipes equinovarus.

## Physical Exam

Z.L. demonstrates a left-sided steppage gait along with an antalgic gait favoring his left side. The gastrocnemius-soleus muscle complex is notably atrophic (Fig. 1).



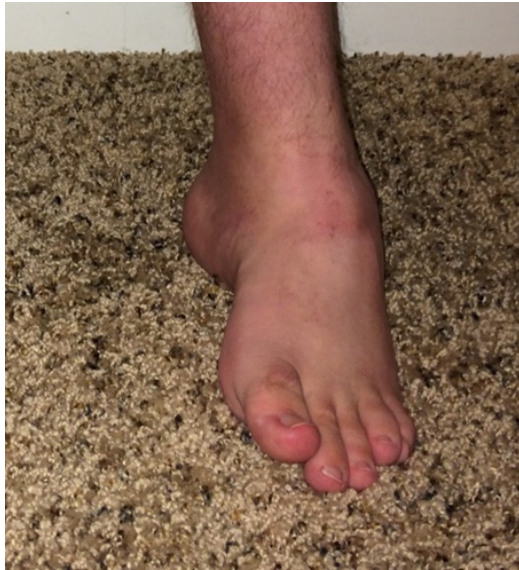**Figure 1:** Clinical weight-bearing view with left foot in equinovarus and gastrocnemius-soleus atrophy.

An apparent equinovarus and pes cavus deformity were also visualized (Fig. 2) on the left foot with minimal ankle dorsiflexion and plantar flexion on passive range of motion.

Z.L. was able to wiggle his toes and was able to achieve 10 degrees of dorsiflexion and 10 degrees of plantar flexion active range of motion at his left ankle. There are no open lesions present on the left foot. Pedal hair growth is present. Dorsalis pedis and posterior tibial pulses are palpable bilaterally. Capillary refill time is less than 3 seconds in all ten toes. Patient has intact light touch and sharp touch sensations to nerve roots T3-S1. Proprioception was present in nerve roots L4-S1. Z.L. had roughly 10 degrees warm to cool touch change from leg to foot bilaterally. A Romberg test was negative. Babinski testing demonstrated down-going toes bilaterally. No clonus was found bilaterally.

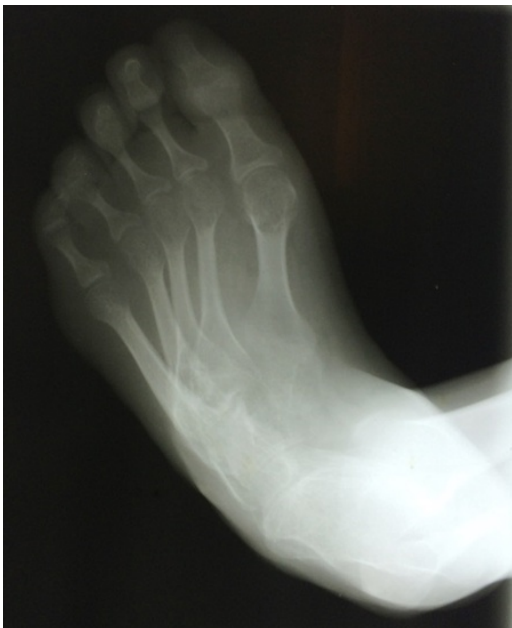Muscle strength of the left foot was graded 4/5 for the tibialis anterior, extensor hallucis longus, extensor digitorum longus and gastrocnemius-soleus complex. Muscle strength of 5/5 was seen in same muscles in the right foot. Knee extension and flexion showed 4/5 strength on the left leg and 5/5 strength on the right

leg. There was no tenderness to palpation bilaterally. A Silfverskiold test demonstrates a rigidity of dorsiflexion consistent with an osseous equinus. These findings demonstrate that Z.L. does not exhibit hemispherical neglect of the left side, likely a result of left cerebral hemisphere compensation.

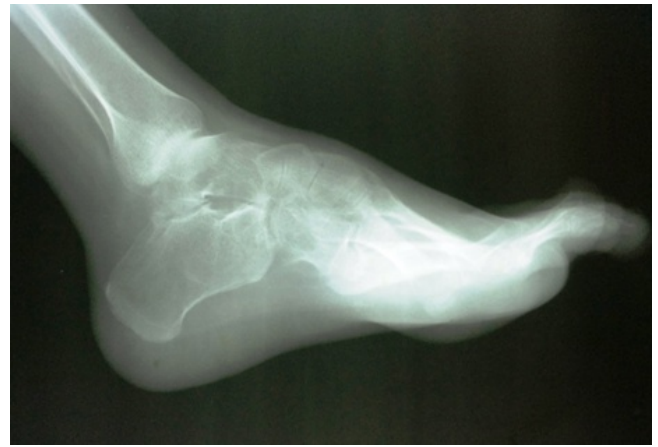

**Figure 2:** Anterior weight-bearing view of left foot with cavus deformity.

Non-weight bearing radiographs demonstrate the pes cavus deformity in the left foot (Fig. 3). The calcaneal inclination angle measured 29 degrees, the angle of Hibbs measured 114 degrees and Meary's angle with the upward convexity, measured 21 degrees (Fig. 4).



**Figure 3:** Anterior-Posterior view of left non-weight bearing foot.



**Figure 4:** Lateral view of non-weight bearing left foot.

### Pathophysiology

“Talipes” is derived from the words talus (ankle) and pes (foot) and combined with equinovarus, describes a foot that is plantar flexed and inverted.[6]

In a neuromuscular equinovarus foot deformity, the neurological deficit to leg and foot muscles results in a condition of overactive muscle tone. Most commonly the foot will develop an equinovarus position. Often the hallux will exhibit hyperextension of the extensor hallucis longus muscle, known as the “Hitchhiker’s Toe,” as part of the deformity.[2] The abnormal positioning of the foot can lead to painful gait and poor balance. Unbalanced muscular action will affect the flexibility of the deformity and thus the treatment modality. Notably, the flexor and adductor muscle groups will overpower the extensor set of muscles resulting in an acquired equinovarus deformity.[3]

### Review of the Research

Current recommendations for flexible foot deformity include bracing or casting. An AFO can be utilized to provide structural support for the flexible equinovarus foot. Home exercises have been shown to enhance strength and motor skills when implementing active and passive stretching.[11] Long-leg orthoses can be used at night, while short-leg orthoses or bracing should be used for weight bearing and ambulation.[10] Z.L. was not born with this deformity, and therefore infantile serial casting was never attempted.

The surgical treatment for acquired talipes equinovarus focuses on release of overly contracted structures.[1,2]

Following failed conservative therapy, soft tissue procedures provide a way of correcting the deformity while avoiding a joint fusion.[4] Achilles tendon lengthening, tibialis anterior transfer and tibialis posterior transfer or recession have been successful in correcting flexible equinovarus.[12] Specifically, the modified Turco procedure offers posterior, medial and subtalar soft tissue contracture release. The Turco procedure has been modified to release the abductor hallucis and plantar fascia to correct fore-foot adduction and has shown 82% good-to-excellent results in one study.[6] Osseous procedures have also been combined with soft tissue releases such as the Evans calcaneocuboid wedge resection and fusion and Ganley's closing abductory cuboid osteotomy.[5] These procedures must be sought out early as a rigid deformity and higher rates of recurrence can develop over time.[12]

A rigid deformity, along with failed conservative treatment or neglected deformity, is a justification for joint destructive procedures.[8] Effective stabilization of the ankle, midfoot and hindfoot have been shown with a pantalar or triple arthrodesis.[7,8] One study observed 86% good-to-excellent satisfaction when compared to preoperative treatment of adult talipes equinovarus following a triple arthrodesis procedure.[9]

## Conclusion

Acquired talipes equinovarus resulting from a neuromuscular disorder can pose a serious problem for normal gait. In flexible cases of foot deformities bracing with physical therapy can improve alignment and motion of the foot and ankle. For more advanced rigid forms of equinovarus it is recommended that surgical intervention be considered to properly repair structural deformities. Current recommendations advise starting with soft tissue releases for more flexible deformities followed by joint destructive procedures as a last resort for a rigid type deformity.[4]

Early recognition and treatment of neuromuscular foot deformities can aid in providing improved gait and decreased pain. In the case of Z.L., he is content with his current level of mobility and has decided to delay surgical intervention for the time being. Z.L. will continue to be monitored and treated for seizure

disorders and will continue conservative therapy until such point that surgical treatment is desired.

## Acknowledgments

Dr. Jarrod Shapiro, DPM, Dr. Dan Leber, OD, Dr. Tom Leber, DVM

## References

- (1) Alvarez RG, Barbour TM, Perkins TD. Tibiocalcaneal arthrodesis for nonbraceable neuropathic ankle deformity. *Foot Ankle Int* 1994;15:354-9.
- (2) Banks HH. The management of spastic deformities of the foot and ankle. *Clin Orthop Relat Res* 1977 ; 122 : 70-76.
- (3) Chang CH, Albarracin JP, Lipton GE, Miller F. longterm follow-up of surgery for equinovarus foot deformity in children with cerebral palsy. *J Pediatr Orthop* 2002 ; 22 : 792-799
- (4) Ghali N, Smith R, Clayden A, Silk F. The Results of Pantalar Reduction In The Management Of Congenital Talipes Equinovarus. *Journal of Bone and Joint Surgery*. 1983.(65)1.
- (5) Huang P, Fu Y, Lu C, Wu C, W W, C Y. Hindfoot Arthrodesis for Neuropathic Deformity. *Kaohsiung Journal of Medical Science*. 2007; 23:120-7.
- (6) Hussain S, Khan M, Ali M, Shahabuddin. Modified Turco's Postero-Medial Release For Congenital Talipes Equino-Varus. *J Ayub Med Coll Abbottabad* 2008;20(30).
- (7) Leal LO, Cangiano SA. Pantalar arthrodesis. *Clin Podiatr Med Surg*. 1991;8:701-15
- (8) Provelengios S, Papavasiliou K, Kyrkos M, Kirkos J, Kapetanios G. The Role of Pantalar Arthrodesis in the Treatment of Paralytic Foot Deformities. *Journal of Bone and Joint Surgery*. 2009 March 1. 91(3):575-583
- (9) Ramseier L, Schoeniger R, Vienne P, Espinosa N. Treatment of late recurring idiopathic clubfoot deformity in adults. *Acta Orthopaedica Belgica*. 2007(73)641-647.
- (10) Samilson RL, Sankaran B, Bersani FA, Smith AD. Orthopaedic management of neuropathic joints. *AMA Arch Surg* 1959;78:115-21.
- (11) Stoffel A: The Treatment of Spastic Contractures. *AmJ Orthop Surg* 70, 6ti.. 1913.
- (12) Synder M, Kumar SJ, Stecyk MD. Split Tibialis posterior tendon transfer and tendo-Achillis lengthening for spastic equinovarus feet. *Journal of Pediatric Orthopedics*. 1993. Jan-Feb; 13(1):20-3.

# Management of Lower Extremity Fracture Blisters

Dayna Chang, MS3 · Western University of Health Sciences, College of Podiatric Medicine

## INTRODUCTION

The treatment of fracture blisters is a topic that has remained controversial both in podiatric and orthopedic literature. Limited research has been done in the area of blister management, and when it comes to the types of approaches available, there are a variety of options, ranging from leaving it intact, bedside debridement, surgical delay, or incising through the blister. Although there is no final consensus on how best to handle blisters at this time, it is extremely important to give consideration to this issue given their potential risk of infection and complications. Therefore, the purpose of this article is to explore the nature of fracture blisters, review the management options available, and thus, gain greater discernment when deciding how best to treat them when faced with such an issue.

## ETIOLOGY

Fracture blisters are the result of epidermal necrosis when there is separation at the epidermal-dermal junction of skin after high energy trauma.<sup>1</sup> Often the trauma involves shear or torque components, such as with falls or motor vehicle accidents.<sup>1</sup> The true etiology of blister formation is unknown; however there are currently two hypotheses – either the blister is caused by the direct mechanical shear of the skin during injury, or it is a mechanism to release pressure from post-traumatic edema.<sup>2</sup> On average, fracture blisters typically appear within 24-48 hours following injury. However, cases have been reported as early as 6 hours after injury, or even as late as 3 weeks.<sup>2</sup>

According to a study by Varela, the incidence of fracture blisters in the lower extremity was 4.2% with ankle fractures, 10.9% with calcaneal fractures, and 29.4% in pilon fractures.<sup>3</sup> They often develop around the ankles, where there is absence of adipose or muscular layers. These layers, when present elsewhere on the body, help skin in the protection of deeper structures. The medial malleolus and the

lateral calcaneus are especially vulnerable given that the skin is much thinner in these locations. For example, the skin over the medial malleolus is approximately 1.5 to 2.5 mm in thickness, compared to the soles and palms, which measure about 5 mm.<sup>1</sup> The medial malleolus has additional characteristics that make it susceptible to fracture blisters. This includes an extensive venous plexus that upon rupture, can lead to extensive hemorrhage, venous obstruction, and arterial spasm.<sup>1</sup> And finally, the lack of hair follicles around the ankles deprive the area of a major source of epithelial cells, which can assist in the re-epithelialization of wounds. Hair follicles can also help anchor the epidermal-dermal junction, which is vital in maintaining skin integrity during trauma.<sup>4</sup>

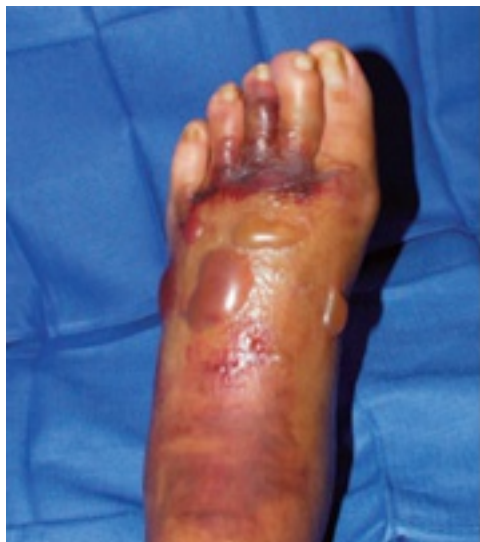## TYPES OF FRACTURE BLISTERS

There are two major types of fracture blisters – serous and hemorrhagic. The major difference between the two is the extent of separation at the epidermal-dermal junction.

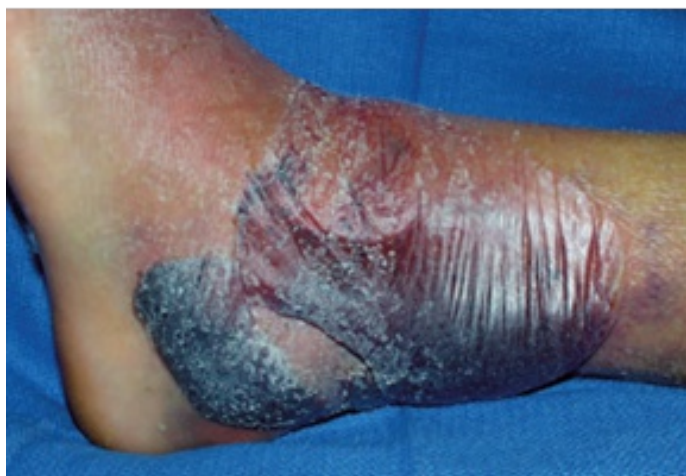Serous, or clear fluid filled, blisters result from a partial separation at the dermis from the epidermis (Figure 1). Giodarno et al. conducted a clinical and histological study comparing the two types of blisters, and they found that the serous blisters, upon gross inspection, showed erythema but no areas of punctate bleeding when unroofed. With closer examination, there was minimal damage at the dermal level with absence of edema, hemorrhage, vascular damage, inflammation, or cellular death. Histologically, the dermis retained epithelial cells that can play a major role in speeding up the recovery process of the blister bed through re-epithelialization.<sup>5</sup> These serous blisters typically heal without scarring or pigmentation changes to skin.<sup>2</sup>

Hemorrhagic, or blood filled, blisters result from complete separation of the dermis from epidermis (Figure 2). Giodarno et al. found that in contrast to the serous blisters, gross inspection of the unroofed

blister bed showed significant erythema with areas of punctate bleeding. Upon histological inspection, there were no remaining epidermal cells attached to the dermis.<sup>5</sup> What makes the injury more significant in hemorrhagic blisters is that there is damage of the vasculature in the papillary dermis. This leads to bleeding in the blister cavity, necrosis of the entire epidermis, and thus, possible dermal scarring and pigmentation changes. The complete detachment of the epithelial cells can also decrease re-epithelization and healing time.<sup>2</sup>



**Figure 1:** Clinical image of serous blisters.<sup>2</sup>



**Figure 2:** Clinical image of a hemorrhagic blister associated with a closed bimalleolar fracture.<sup>2</sup>

## CONCERNS

The major concern with fracture blisters is that although the fluid contained within the blister is sterile, upon rupture, it becomes an ideal culture medium for contaminating organisms. The most common infecting organisms are *S. aureus* and *S.*

*epidermidis*, which are a part of the resident skin flora.<sup>2</sup> Skin compromise thus becomes a serious concern when planning bedside aspiration, de-roofment, or surgical incisions.

## PREVENTION

If a blister has not yet formed in the presence of a lower extremity fracture, precautions should be taken in cases where there is high suspicion of future development. As with any high-energy injury, initial treatment needs to involve RICE therapy – rest, ice, compression, and elevation. Since blisters can form from the edema separating the epidermis from the dermis, RICE therapy helps minimize the compartmental pressure. Early surgical intervention, within 6-8 hours, or up to 24 hours, can also be an ideal management choice.<sup>2</sup> Benefits of early surgery include avoiding incisions through potential fracture blister beds and relieving tissue pressures that are risks for blister formation. It has also been shown to have little potential for blister formation in the future if surgery is done within 24 hours.<sup>2</sup>

## BLISTER TREATMENT

Once a blister is present, there is no accepted guideline regarding what must be done. There are several options one can consider, which include: aspirating the blister, de-roofing the blister, incising through the bed of the fracture blister if deemed clinically necessary during surgery, making incisions avoiding fracture blister sites during surgery, or delaying surgery until the blister is resolved.<sup>2,6</sup>

One major factor in deciding management is what type of fracture it is. In 1994, Giordano et al. compared wound healing complication rates between blood-filled and fluid-filled blisters. It was a prospective study that looked at thirteen ankles with associated fracture blisters. They were all treated with open reduction internal fixation (ORIF), and the blisters were unroofed at the time of surgery. The timing of the surgery was dependent on soft tissue swelling, and incisions were placed in positions best suited for the ORIF. Therefore, timing and incision were not altered by the status of the blister. Twelve of the thirteen cases healed uneventfully within three days, but there was one case of healing complication. This complication occurred through a blood-filled

blister, and therefore, the study concluded that incisions made through blood filled blisters might have a worse prognosis.<sup>4</sup>

A year later, Giordano conducted another prospective study with Koval in 1995 comparing approaches of blister treatment in fifty-three patients. Twenty-three were treated with casts or external fixators, and the other thirty underwent open reduction internal fixation. Nineteen of those underwent early internal fixation, which means that patients were immediately brought into the operating room as soon as swelling permitted. The other eleven patients underwent delayed fixation, which means that patients were brought into the operating room once there was reduction of swelling and re-epithelialization of the fracture bed. In this study, there were a total of seven complications with blister bed healing after being incised, and all were associated with a blood-filled blister. They therefore concluded that there is increased risk of complications when incisions are made through hemorrhagic blisters.<sup>6</sup> Furthermore, two of the seven complications occurred intraoperatively with early fixation. Thus, it may be worth noting that allowing re-epithelialization could potentially minimize poorer outcomes.

In the same study, Giordano and Koval also compared direct blister treatment options, which included aspiration of the blister, de-roofing the blister and applying Silvadene, or just leaving the blister intact. There was no significant difference found in the outcome of these different treatment modalities.<sup>6</sup>

Finally, Strauss et al also evaluated outcomes of lower extremity fractures with blisters. He evaluated forty-seven patients, with forty-five of them undergoing ORIF. Unlike Giordano's study, incisions avoided blisters when possible and timing of surgery depended on resolution of edema and blister re-epithelialization. There were six cases of post-op scarring in regions of the fracture blisters, and all involved hemorrhagic blisters. Thus, they concluded that blood filled blisters had greater post-op scarring, which impacted patient satisfaction.<sup>7</sup>

Thus, the literature has consistently shown that incising through hemorrhagic blisters will lead to greater risk of post-op complications.<sup>4,6,7</sup> The one

study that compared direct blister treatment showed that there was no significant difference if the blister is aspirated, de-roofed, or simply left intact.<sup>6</sup>

## TIMING CONSIDERATIONS

If a patient has a fracture that needs surgery, and a blister is present, one question that will inevitably be asked is how early the patient can be taken to the operating room. First and foremost, swelling will be one of the most vital dictators. One way to test for skin viability is to pinch the skin to see if it wrinkles. If it does, skin turgor is returning to normal limits and edema is resolving.<sup>8</sup> At this point, a surgical incision can be made through a blister, if necessary, with less chance of skin dehiscence, necrosis, or scarring.

In addition, Giordano's study revealed that it could be worth waiting for blister healing and re-epithelialization of the bed.<sup>6</sup> This improves overall health of the skin, which minimizes complications. However, it is important to note that the case should not be prolonged too long because bone fibrosis may develop after fourteen days. Fracture blisters can take this amount of time, or even longer, to resolve.<sup>8</sup> Thus, surgical intervention is a delicate balance between improving soft tissue viability and preventing osseous fibrosis.

## CONCLUSION

With what we currently know about fractures in the established literature, several conclusions can be made. First, prevention of fracture blisters should be initiated through RICE therapy or early surgical intervention. Secondly, there is no difference between the direct treatments of blisters (aspiration vs. de-roofment vs. leaving intact). Theoretically, it may be advantageous to leave the blister intact since it acts as a sterile dressing and prevents introduction of bacteria. Thirdly, if a blister must be incised during a surgical procedure, the type of blister it is (serous vs. hemorrhagic) becomes an important predictor of outcome. Serous blisters have not been associated with increased complications, while on the other hand, hemorrhagic blisters have consistently led to greater risk of post-operative problems. And finally, timing of surgery will need discretion from the doctor, who must balance its urgency, soft tissue viability, and osseous fibrosis.



Ultimately, fracture blister management is controversial with no clear guidelines. The etiology and literature is still limited in this field and there is great potential for further research on this topic.

## REFERENCES

1. Shelton ML, Anderson RL: Complications of Fractures and Dislocations of the Ankle. In: Complications of Orthopaedic Surgery, ed CH Epps Jr, editor. Philadelphia: JB Lippincott; 1988. p. 599-648.
2. Smith TF, Bui RP, Coker CO. Understanding Fracture Blisters: Management and Implications. Podiatry Institute Update – Chapter 28. 2010.
3. Varela CD, Vaughan TK, Carr JB, et al. Fracture blisters: clinical and pathological aspects. J Orthop Trauma. 7:417-427, 1993.
4. Wallace GF, Sullivan J: Fracture blisters. Clin Pod Med Surg. 12(4):801-812, 1995.
5. Giordano CP, Koval KJ, Zuckerman JD, et al. Fracture blisters. Clin Orthop Relat Res. 1994;307:214-221.
6. Giordano CP, Koval KJ. Treatment of Fracture Blisters: A Prospective Study of 53 Cases. J Orthop Trauma 1995;9:171-6.
7. Strauss EJ, Petrucelli G, Bong M, et al. Blisters Associated with Lower-Extremity Fracture: Results of a Prospective Treatment Protocol. J Orthop Trauma. 2006;20:618-622.
8. Zirm, RJ. Fracture Blisters. Podiatry Institute Update – Chapter 47. 2001.





---

# EXTREMITAS

*Journal of Lower Limb Medicine*

---

Thank you for reading!

If you have any questions or comments about the content of this volume, please feel free to email our editing staff at [extremitasjournal@westernu.edu](mailto:extremitasjournal@westernu.edu); we will be happy to get back to you.

If you have a topic of interest regarding lower limb medicine, consider submitting your original articles, case studies, reviews, or any other formats that utilize evidence based practices to Extremitas. Be on the lookout for announcements regarding submission requirements and deadlines in the fall semester.

We appreciate your support and readership and look forward to another successful year sharing in WesternU's tradition of academic scholarship with you.

The Extremitas Journal Staff

## Leading Podiatry Conferences

## OUR MISSION

### Residency Education Summit - East\*

August 14-16, 2015  
Teaneck Marriott at Glenpointe  
Teaneck, New Jersey  
ResEdSummitEast.com

### SuperbonesSuperwounds West

October 22-24, 2015  
The Cosmopolitan Hotel  
Las Vegas, Nevada  
SuperbonesSuperwoundsWest.com

### Desert Foot

November 18-20, 2015  
Sheraton Downtown  
Phoenix, Arizona  
DesertFoot.org

### SuperbonesSuperwounds East

March 2016  
SuperbonesSuperwoundsEast.com

### Residency Education Summit - Midwest\*

Summer 2016  
ResEdSummitMidwest.com

PRESENTConferences.com



**\*Residents:** FREE Hotel (maximum of 3 nights);  
2 Residents must be registered for the  
conference and share a room.

**Residency Directors:** Registration Fee waived if your  
program is subscribed to PRESENT Podiatric Residency  
Education Online – or if not subscribed, 2 or more Residents  
from your program attend the conference.

**REGISTRATION IS ALWAYS FREE  
FOR RESIDENTS AND STUDENTS**

Providing the standard  
online lecture curriculum  
to podiatric residency  
programs nationwide

Dedicated to improving  
the knowledge and skills of  
footcare professionals  
throughout the world

Fostering collaboration to  
improve skills of residents  
and practicing podiatrists

A pioneer in integrating  
social networking with  
online medical education

PRESENT e-Learning Systems  
5301 N Federal Highway  
Suite 150  
Boca Raton, FL 33487  
info@presentelearning.com  
888.802.6888

Podiatry.com

## Leading Podiatric Website

Sign up for **FREE** and receive the same PRESENT Podiatry eZines  
read by podiatric residents and leading podiatrists around the country.

*This Week in Podiatric Residency Education, Practice Perfect, Residency Insight, Paths to Perfection  
and The Journal of Diabetic Foot Complications* have set the standard for online Podiatry Newsletters.

Go to [Podiatry.com](http://Podiatry.com) to sign up and have them delivered via email for free.  
There's no obligation, we honor your privacy and you can unsubscribe at any time.

